

Original Research Article

## Hepatoprotective effect of *Rosa canina* fruit extract against carbon tetrachloride induced hepatotoxicity in rat

Heibatollah Sadeghi<sup>1,2</sup>, Saleh Hosseinzadeh<sup>3</sup>, Mehdi Akbartabar Touri<sup>4</sup>, Mehdi Ghavamzadeh<sup>3</sup>, Mehrzad Jafari Barmak<sup>2</sup>, Moslem sayahi<sup>3</sup>, Hossein Sadeghi<sup>1,5</sup>\*

<sup>1</sup>Medicinal Plants Research Center, Yasuj University of Medical Sciences, Yasuj, Iran

<sup>2</sup>Cellular and Molecular Research Center, Yasuj University of Medical Sciences, Yasuj, Iran

<sup>3</sup>Student Research Committee, Yasuj University of Medical Sciences, Yasuj, Iran

<sup>4</sup>Social Determinants of Health Research Center, Yasuj University of Medical Sciences, Yasuj, Iran

<sup>5</sup>Department of Pharmacology, Faculty of Medicine, Yasuj University of Medical Sciences, Yasuj, Iran

### Article history:

Received: Oct 15, 2014

Received in revised form:

Apr 25, 2015

Accepted: Jul 14, 2015

Vol. 6, No. 2, Mar-Apr 2016,  
181-188.

### \* Corresponding Author:

Tel: 098 7433230290

Fax: 0987433235153

H\_sadeghi\_m@yahoo.com

### Keywords:

Hepatoprotective

Tetrachloride

*Rosa canina* fruit

Rats

### Abstract

**Objective:** The present study was conducted to investigate the hepatoprotective activity of hydro-ethanolic fruit extract of *Rosa canina* (*R. canina*) against carbon tetrachloride (CCl<sub>4</sub>)-induced hepatotoxicity in rats.

**Materials and Methods:** Male Wistar albino rats were randomly divided into six groups of 8 animals of each, including control, toxic (CCl<sub>4</sub>), *R. canina* 250, 500, and 750 mg/kg + CCl<sub>4</sub> and *R. canina* 750 mg/kg alone. *R. canina* (p.o., daily) and CCl<sub>4</sub> (1 ml/kg twice a week, 50% v/v in olive oil, i.p.) were administered to animals for six weeks. Serum analysis was performed to assay the levels of aspartate aminotransferase (AST), alanine amino transaminase (ALT), alkaline phosphatase (ALP), albumin (ALB), total protein (TP) and malondialdehyde (MDA). Biochemical observations were also supplemented with histopathological examination (haematoxylin and eosin staining) of liver section.

**Results:** Hepatotoxicity was evidenced by considerable increase in serum levels of AST, ALT, ALP, and lipid peroxidation (MDA) and decrease in levels of ALB and TP. Injection of CCl<sub>4</sub> also induced congestion in central vein, and lymphocyte infiltration. Treatment with hydro-alcoholic fruit extract of *R. canina* at doses of 500 and 750 mg/kg significantly reduced CCl<sub>4</sub>-elevated levels of ALT, AST, ALP and MDA (p<0.01). The extract also increased the serum levels of ALB and TP compared to CCl<sub>4</sub> group (p<0.01) at the indicated dose. Histopathological studies supported the biochemical finding.

**Conclusion:** Our finding indicated hepatoprotective effects of the hydro-alcoholic fruit extract of *R. canina* on CCl<sub>4</sub>-induced hepatic damage in rats and suggested that these effects may be produced through reducing oxidative stress.

Please cite this paper as:

Sadeghi H, Hosseinzadeh AS, Akbartabar Touri M, Ghavamzadeh M, Jafari Barmak M, sayahi M, Sadeghi H. Hepatoprotective effect of *Rosa canina* fruit extract against carbon tetrachloride induced hepatotoxicity in rat. Avicenna J Phytomed, 2016; 6 (2): 181-188.

## Introduction

Liver is the most important metabolic organ in the body. It plays a major role in the metabolism, detoxification, storage and secretory functions in the body of animals (Swarnalatha and Reddy 2012). Various xenobiotics or oxidative stress can produce deleterious effects on these important functions of liver (Kale et al., 2012). Despite improvement in the pharmaceutical sciences, hepatic disease remains as an unsolved worldwide health problem. Thus searching for new treatment is still ongoing. Nowadays, herbal medicines are one of the main options for prevention or treatment of liver disorders because of their multiple beneficial properties such as antioxidant and anti-inflammatory activities (Jaishree and Badami 2010; Pareek et al., 2013).

*Rosa canina L.* is a shrub of the Rosaceae family that grows in Europe, western Asia and north-eastern Africa. Rose fruit is traditionally used as diuretic, laxative, and the management of gallstones, arthritis, gout, fever, colds (Orhan et al., 2007; Chrubasik et al., 2008; GHIORGHITĂI et al., 2012). Phytochemical analysis of the fruit extract of *R. canina* indicated the presence of flavonoids, phenolic acids, tannins, carotenoids, fatty acids, phospholipids, galactolipids, minerals, vitamins (particularly vitamin C and also vitamins B1, B2, K, PP, E) in the extract (Demir and Özcan 2001; Lattanzio et al., 2011). *R. canina* is well-known for its high phenolic contents (Roman et al., 2013). These compounds constitutes an important class of known natural antioxidants that exhibit various important physiological and biological properties in *in-vivo* and *in-vitro* (Campos-Vega et al., 2010). Antioxidant activity of the *R. canina* fruit extract has been documented in several studies (Kilicgun and Altiner 2010; Naser et al., 2011; Fattahi et al., 2012; Roman et al., 2013). Moreover, many natural agents with antioxidant activity have been proposed to prevent and cure

hepatotoxicity induced by different toxins (Akindele et al., 2010, Murat Bilgin et al., 2011, Bachar et al., 2012, Ottu et al., 2013). Therefore, the present study was designed to examine the potential hepatoprotective effects of hydro-alcoholic extract of *R. canina* fruit on hepatotoxicity induced by carbon tetrachloride (CCl<sub>4</sub>) in rats.

## Materials and Methods

### Plant material

The fruit of *R. canina* was collected in October 2013 from Dena Mountains, Kohgiluyeh and Boyerahmad province, Iran. The collected parts were neatened and shade dried.

### Extract preparation

At first, the dried fruits of *R. canina* have been grinded. The powdered *R. canina* fruit was macerated for 48 h in ethanol/water (50/50, v/v) at room temperature and then percolated. Next, for the second time, adequate 50% ethanol was added to residual crushed material for 24 h and subsequently re-percolated. The extract solution was collected and concentrated using a rotary evaporator (Hyedolph, type: HeizbadHei-VAP, Germany) at 40°C under reduced pressure. Finally, the extract was weighted and stored at -20°C (Sadeghi et al., 2014).

### Chemicals

Carbon tetrachloride (CCl<sub>4</sub>), Trichloroacetic acid (TCA), thiobarbituric acid (TBA), diethyl ether and other solvents were obtained from Merck, Germany. The assay kits for the determination of ALT, AST, ALP, ALB and TP were purchased from Pars Azmun, Tehran, Iran.

### Experimental animals

Forty eight male albino Wistar rats (180–220 g) were purchased from Razi Institute of Iran (Tehran, Iran). The animals were maintained under standard

## Hepatoprotective effect of *Rosa canina* fruit

environmental conditions and were allowed to take standard laboratory feed, and tap water.

### Hepato-protective activity

The rats were randomly divided into six groups of eight animals per each. Treatment was carried out according to following groups for six weeks:

Group I (control group) received olive oil.

Group II (hepatotoxic group) received i.p. injection of CCl<sub>4</sub> (50% v/v in olive oil, 1 ml/kg twice a week (AkbartabarToori et al., 2015).

Groups III–V (the extract groups) received CCl<sub>4</sub> plus *R. canina* (p.o., daily) extract at doses of 250, 500 and 750 mg/kg (Deliorman Orhan et al., 2007).

Group VI only received *R. canina* fruit extract at doses of 750 mg/kg

### Assessment of liver function parameters

Twenty-four hours after the last dose of the CCl<sub>4</sub> and *R. canina* extract, blood samples were collected by cardiac puncture. Then, the animals were euthanized by an overdose of diethyl ether. In order to serum separation the blood was allowed to coagulate at room temperature for 30 min and then centrifuged at 2000 rpm for 15 min. The serum was evaluated for levels of ALT, AST, ALP, ALB and TP using pars azmun diagnostic kits, Tehran, Iran, according to the method described by the manufacturers.

### Determination of lipid peroxidation

The measurement of serum MDA level was performed according to the method previously described (Buege and Aust 1978). According to this method, 375 mg of TBA was dissolved in 2 mL of chlorhydric acid (HCl, 0.25 N), followed by 15 g of trichloroacetic acid (TCA) for a total volume of 100 mL. The solution was heated in a water bath at 50 °C till TBA properly dissolved. Then, 1 mL of serum was mixed with 2 mL of TCA—TBA—HCl. Next, the solution was heated for 15

min in a boiling water bath. After cooling, the flocculent precipitate was removed by centrifugation (1700×g, 15 min). Finally the absorption of supernatant was determined at 535 nm against a blank that contained all reagents except the serum sample. Serum MDA concentration was expressed as nmol/ml (Sharma et al., 2006).

### Histological studies

After euthanizing the animals, livers were carefully removed and fixed in 10% buffered formaldehyde solution for 1 week. Then, the fixed biopsies were embedded in paraffin and cut into 3–4 mm slices. The slices were mounted on glass slides and stained with hematoxylin and eosin for pathological analysis. The images were examined under light microscope (Sadeghi et al., 2014)

### Statistical analysis

The data were expressed as the mean±SD. The differences between the control and treatment groups were tested by ANOVA followed by the Tamhane's post-hoc test, using SPSS 16.0 software.  $p < 0.05$  was considered to show significant differences for all comparisons.

## Results

### Assessment of liver function parameters

As shown in Table 1, i.p. injection of CCl<sub>4</sub> significantly ( $p < 0.001$ ) increased the serum levels of ALT, AST and ALP in toxic group, compared to the control group. The serum levels of ALB and TP was significantly decreased because of intoxication with CCl<sub>4</sub> ( $p < 0.01$ ). *R. canina* fruit extract at doses of 500 and 750 mg/kg markedly inhibited the CCl<sub>4</sub>-induced liver injury according AST, ALT and ALP ( $p < 0.01$ ,  $p < 0.001$ , respectively). *R. canina* considerably increased the diminished serum levels of ALB at doses of 500 and 750 mg/kg ( $p < 0.05$  and  $p < 0.01$  respectively). The extract also increased the serum levels of TP at the indicated doses

compared to the toxic group, although this effect was statistically significant only at the dose of 750 mg/kg ( $p < 0.001$ ). Additionally, the administration of *R.*

*canina* alone (750 mg/kg, Group VI) did not show any effect on the serum levels of ALT, AST, ALP, ALB and TP compared to control group.

Table 1. Effect of *Rosa canina* fruit extract on serum biochemical parameters in CCl<sub>4</sub>-induced hepatotoxicity in rats.

Treatment group	Dose (per kg)	ALT (U/l)	AST (U/l)	ALP (U/l)	ALB(g/dl)	TP (g/dl)
Control	1 ml vehicle	72.4 ± 4.07	146.6 ± 18.73	259.4 ± 44.08	3.38 ± 0.14	7.06 ± 0.32
CCl <sub>4</sub>	CCl <sub>4</sub> in olive oil (1:1) 1 ml	167.3 ± 20.41 <sup>***</sup>	252 ± 32.46 <sup>***</sup>	591.4 ± 46.99 <sup>***</sup>	2.72 ± 0.22 <sup>**</sup>	6.34 ± 0.20 <sup>**</sup>
RC + CCl <sub>4</sub>	250 mg; 1 ml	129.9 ± 17.72 <sup>**</sup>	228.8 ± 32.66 <sup>*</sup>	513.7 ± 64.24 <sup>***</sup>	2.88 ± 0.09 <sup>***</sup>	6.35 ± 0.13 <sup>*</sup>
RC + CCl <sub>4</sub>	500 mg; 1 ml	85.6 ± 9.75 <sup>c</sup>	177.7 ± 48.29	412.4 ± 72.29 <sup>**b</sup>	3.14 ± 0.05 <sup>a</sup>	6.87 ± 0.36
RC + CCl <sub>4</sub>	750 mg; 1 ml	74.4 ± 8.38 <sup>c</sup>	166.7 ± 24.16 <sup>b</sup>	310.1 ± 59.32 <sup>c</sup>	3.45 ± 0.08 <sup>b</sup>	7.19 ± 0.29 <sup>c</sup>
RC only	750 mg	64.8 ± 3.87 <sup>c</sup>	152.2 ± 18.51 <sup>b</sup>	273.2 ± 41.15 <sup>c</sup>	3.41 ± 0.07 <sup>b</sup>	7.01 ± 0.30 <sup>a</sup>

The values are reported as the mean ± SD (n = 8) RC, hydro-alcoholic extract from *Rosa canina* fruit; ALT, alanine aminotransferase; ALP, alkaline phosphatase; AST, aspartate aminotransferase; ALB, albumin; TP, total protein; MDA, malondialdehyde. \*  $p < 0.05$ , \*\*  $p < 0.01$ , \*\*\*  $p < 0.001$  vs. control group. a  $p < 0.05$ , b  $p < 0.01$ , c  $p < 0.001$  vs. CCl<sub>4</sub> group

### Determination of lipid peroxidation

Lipid peroxidation was determined by measurement of malondialdehyde (MDA) concentration in plasma. As shown in Fig 1, a significant increase in the serum level of MDA was observed in rats intoxicated with CCl<sub>4</sub> when compared with the control group ( $p < 0.001$ ). Treatment of the animals with *R. canina* at doses of 500 and 750 mg/kg inhibited the increase in serum levels of MDA due to injection of CCl<sub>4</sub> ( $p < 0.001$ ). There was no difference in MDA serum levels in the rats treated with *R. canina* alone (750 mg/kg) and control group.

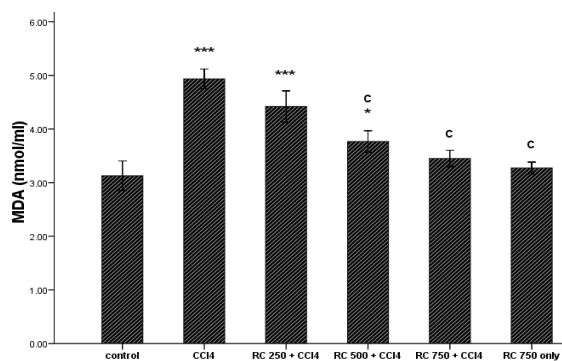


Figure 1. Effect of *Rosa canina* fruit on serum malondialdehyde (MDA) level in CCl<sub>4</sub>-treated rats. Data express the mean ± S.D. \*  $p < 0.05$  and \*\*\*  $p < 0.001$  vs. control group. C,  $p < 0.001$  vs. CCl<sub>4</sub> group

### Histopathological studies

As illustrated in Fig.2, histological assessment of the liver sections revealed that injection of CCl<sub>4</sub> induced pathological changes such as loss of cellular boundaries, congestion in central vein, destroyed lobular structure and lymphocyte infiltration. Treatment of the animals with *R. canina* at doses of 500 and 750 mg/kg reversed the hepatic damage induced by CCl<sub>4</sub> towards normal. However, the extract of *R. canina* fruit at dose of 250 mg/kg did not show a considerable protective effect on the pathological changes induced by CCl<sub>4</sub>. Moreover, administration of the extract alone (750 mg/kg) did not produce any liver damage compared to control group.

### Discussion

The results of the present study clearly indicated hepatoprotective effects of the ethanolic extract of *R. canina* fruit against CCl<sub>4</sub>-induced hepatic damage in rats. Hepatotoxicity induced by CCl<sub>4</sub> is one of the best characterized systems of xenobiotic-induced hepatotoxicity in experimental animals. This method usually used to evaluation hepatoprotective

## Hepatoprotective effect of *Rosa canina* fruit

properties of many bioactive substances and medicinal plants (Huang et al., 2013). It has been reported that lipid peroxidation, reducing activity of antioxidant enzymes and generation of free radicals are the primary reasons of CCl<sub>4</sub>-induced hepatic injury (Srivastava and Shivanandappa 2006). These changes are similar to those observed during cellular oxidative stress, which is considered to have an important role in the pathogenesis of many disorders such as hepatic injuries (Wu et al., 2007).

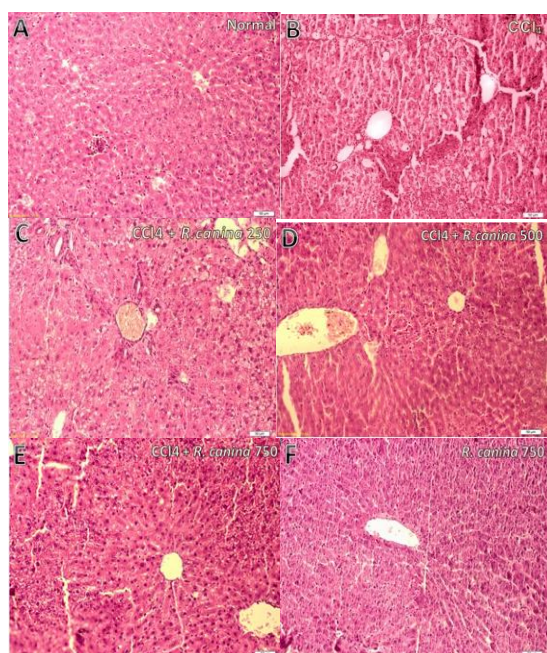


Figure 2. Effect of *R. canina* fruit extract on CCl<sub>4</sub> induced hepatotoxicity in rats. The liver slices of rats were mounted on glass slides and stained with hematoxylin and eosin. The images were examined under light microscope. Intoxication with CCl<sub>4</sub> induced pathological changes such as loss of cellular boundaries, congestion in central vein, destroyed lobular structure and lymphocyte infiltration (B). Treatment of the animals with *R. canina* at doses of 500 and 750 mg/kg reversed the hepatic damage induced by CCl<sub>4</sub> towards normal (D,F). A : Control group, B: CCl<sub>4</sub> group, C: CCl<sub>4</sub>+ *R. canina* 250 mg/kg D: CCl<sub>4</sub>+ *R. canina* 500 mg/kg, E: CCl<sub>4</sub> + *R. canina* 750 mg/kg, F: *R. canina* 750 mg/kg alone.

In this study, CCl<sub>4</sub> intoxication considerably raised the serum levels of ALT, AST and ALP in the animals, a marker of cellular leakage and failure in activities of cell membrane in liver

(Mujahid et al., 2013). These results are in good agreement with previous studies. Yang and co-workers showed that intoxication of rats with CCl<sub>4</sub> increases levels of ALT, AST and ALP in serum indicate liver damage (Yang et al., 2011). Furthermore, reduction of ALB and TP by CCl<sub>4</sub> is a further indication of liver injury. CCl<sub>4</sub> causes disruption and disassociation of polyribosomes on endoplasmic reticulum which lead to reducing the biosynthesis of protein (Sathesh Kumar et al., 2009). Treatment with the fruit extract of *R. canina* at 500 and 750 mg/kg doses significantly inhibited the increase in the levels of these marker enzymes, implying protection against liver damage. Therefore, it is possible that the extract stabilizes the plasma membrane or repairs the hepatic tissue injuries induced by CCl<sub>4</sub>. Injection of CCl<sub>4</sub> also caused a significant reduction in the serum levels of TP and ALB, further indicator of liver toxicity (Ravikumar and Gnanadesigan 2012). The extract reversed the CCl<sub>4</sub>-induced decrease of serum levels of TP and ALB towards normal.

As mentioned above, generation of reactive oxygen species and lipid peroxidation participate in the liver toxicity of CCl<sub>4</sub>. MDA is a secondary product of poly-unsaturated fatty acids peroxidation (Amat et al., 2010) and serves as a main marker to estimate the levels of lipid peroxidation (Cho et al., 2013). In addition, the level of lipid peroxidation is a measure of membrane damage and shows alteration in structure and function of cellular membrane (Kepekçi et al., 2013). In the present study the fruit extract of *R. canina* at the doses of 500 and 750 mg/kg significantly prevented the raise in serum levels of MDA due to intoxication with CCl<sub>4</sub> in the rats. It is important to notice that the fruits of *R. canina* are rich in Phenolic compounds (Hvattum 2002, Fecka 2009) which exhibit a variety of biological and pharmacological activities, including anti-inflammatory and anti-bacterial activities (Zdařilová et al., 2009). Furthermore, antioxidant activity of *R.*

*canina* has been reported in some studies (Daels-Rakotoarison et al., 2002, Serteser et al., 2009, Kilicgun and Altiner 2010). Also, it has been revealed that radical scavenging capacities of *R. canina* extracts positively correlated with phenolic content (Wenzig et al., 2008, Fattahi et al., 2012). Hence, it is possible that the hepatoprotective activity of the *R. canina* fruit extract to some extent, is mediated by the scavenging free radical activity of the extract.

Histopathological examination of liver sections confirmed our biochemical findings. Injection of CCl<sub>4</sub> induced a variety of hepatic histological changes including congestion in central vein, destroyed lobular structure and leucocyte infiltration. These changes were significantly attenuated by the *R. canina* fruit extract.

In conclusion, the results of the present study demonstrate hepatoprotective effects of the ethanolic extract of *R. canina* fruit on CCl<sub>4</sub>-induced hepatic damage in rats. These protective effects may be, at least in part, related to antioxidant properties of the extract.

### Conflict of interest

Authors declare no conflict of interest.

### Acknowledgments

The authors wish to thank the research council of the Yasuj University of Medical Sciences for providing the financial support for this study.

### References

- Akbartabar Toori M, Joodi B, Sadeghi H, Sadeghi H, Jafari M, Talebianpoor MS, Mehraban F, Mostafazadeh M, Ghavamizadeh M. 2015. Hepatoprotective activity of aerial parts of *Otostegia persica* against carbon tetrachloride-induced liver damage in rats. *Avicenna J Phytomed*, 5:238-246.
- Akindele AJ, Ezenwanebe KO, Anunobi CC, Adeyemi OO. 2010. Hepatoprotective and in vivo antioxidant effects of *Byrsocarpus coccineus* Schum. and Thonn. (Connaraceae), *J Ethnopharmacol*, 129: 46-52.
- Amat N, Upur H, Blazeković B. 2010. In vivo hepatoprotective activity of the aqueous extract of *Artemisia absinthium* L. against chemically and immunologically induced liver injuries in mice. *J Ethnopharmacol*, 131: 478-484.
- Mahmud Z, Bachar S, Qais N. 2012. Antioxidant and Hepatoprotective Activities of Ethanolic Extracts of Leaves of *Premna esculenta* Roxb. against Carbon Tetrachloride-Induced Liver Damage in Rats. *J Young Pharm*, 4: 228-234.
- Buege, J. and Aust S. 1978. The thiobarbituric acid assay. *Methods Enzymol*, 52: 306-307.
- Campos-Vega R, Loarca-Piña G, Oomah BD. 2010. Minor components of pulses and their potential impact on human health. *Food Res Int*, 43: 461-482.
- Cho BO, Ryu HW, So Y, Jin CH, Baek JY, Park KH, Byun EH, Jeong IY. 2013. Hepatoprotective effect of 2,3-dehydrosilybin on carbon tetrachloride-induced liver injury in rats. *Food Chem*, 138: 107-115.
- Chrubasik C, Roufogalis BD, Müller-Ladner U, Chrubasik S. 2008. A systematic review on the *Rosa canina* effect and efficacy profiles. *Phytother Res*, 22: 725-733.
- Daels-Rakotoarison DA, Gressier B, Trotin F, Brunet C, Luyckx M, Dine T, Bailleul F, Cazin M, Cazin JC. 2002. Effects of *Rosa canina* fruit extract on neutrophil respiratory burst. *Phytother Res*, 16: 157-161.
- Demir, F. and Özcan M. 2001. Chemical and technological properties of rose (*Rosa canina* L.) fruits grown wild in Turkey. *J Food Eng*, 47: 333-336.
- Deliorman Orhan D, Hartevioğlu A, Küpeli E, Yesilada E. 2007. In vivo anti-inflammatory and antinociceptive activity of the crude extract and fractions from *Rosa canina* L. fruits. *J Ethnopharmacol*, 112:394-400.
- Fattahi, S, Jamei, R, Hosseini Sarghein S. 2012. Antioxidant and antiradical activities of *Rosa canina* and *Rosa*

## Hepatoprotective effect of *Rosa canina* fruit

- pimpinellifolia fruits from West Azerbaijan. *IJPP*, 2: 523-529.
- Fecka, I. 2009. Qualitative and quantitative determination of hydrolysable tannins and other polyphenols in herbal products from meadowsweet and dog rose. *Phytochem Anal*, 20: 177-190.
- Ghiorghita G, Maftel DE, Nicuta D, Rati V. 2012. Study of several parameters in *Rosa canina* L. genotypes from native habitats in Romania and the in vitro response of this species. *Acad Roman Sci Ann - Series Biol Sci*, 1: 91-109.
- Huang GJ, Deng JS, Huang SS, Lee CY, Hou WC, Wang SY, Sung PJ, Kuo YH. 2013. Hepatoprotective effects of eburicoic acid and dehydroeburicoic acid from *Androdia camphorata* in a mouse model of acute hepatic injury. *Food Chem*, 141: 3020-3027.
- Hvattum E. 2002. Determination of phenolic compounds in rose hip (*Rosa canina*) using liquid chromatography coupled to electrospray ionisation tandem mass spectrometry and diode-array detection. *RCM*, 16: 655-662.
- Jaishree V and Badami S. 2010. Antioxidant and hepatoprotective effect of swertiamarin from *Enicostemma axillare* against d-galactosamine induced acute liver damage in rats. *J Ethnopharmacol*, 130: 103-106.
- Kale I, Asif Khan M, Irfan Y, Veerana GA. 2012. Hepatoprotective potential of ethanolic and aqueous extract of flowers of *Sesbania grandiflora* (Linn) induced by CCl<sub>4</sub>. *Asian Pac J Trop Biomed*, 2: S670-S679.
- Kepekçi RA, Polat S, Çelik A, Bayat N, Saygideger SD. 2013. Protective effect of *Spirulina platensis* enriched in phenolic compounds against hepatotoxicity induced by CCl<sub>4</sub>. *Food Chem*, 141: 1972-1979.
- Kilicgun H, and Altiner D. 2010. Correlation between antioxidant effect mechanisms and polyphenol content of *Rosa canina*. *Pharmacogn Mag*, 6: 238.
- Lattanzio F, Greco E, Carretta D, Cervellati R, Govoni P, Speroni E. 2011. In vivo anti-inflammatory effect of *Rosa canina* L. extract. *J Ethnopharmacol*, 137: 880-885.
- M, Siddiqui HH, Hussain A, Hussain MS. 2013. Hepatoprotective effects of *Adenantha pavonina* (Linn.) against anti-tubercular drugs-induced hepatotoxicity in rats. *Phcog J*, 5: 286-290.
- Murat Bilgin H, Atmaca M, Deniz Obay B, Ozekinci S, Taşdemir E, Ketani A. 2011. Protective effects of coumarin and coumarin derivatives against carbon tetrachloride-induced acute hepatotoxicity in rats. *Exp Toxicol Pathol*, 63: 325-330.
- Montazeri N, Baher E, Mirzajani F, Barami Z, Yousefian S. 2011. Phytochemical contents and biological activities of *Rosa Canina* fruit from Iran. *J Med Plant Res*, 5: 4584-4589.
- Deliorman Orhan D, Hartevioğlu A, Küpeli E, Yesilada E. 2007. In vivo anti-inflammatory and antinociceptive activity of the crude extract and fractions from *Rosa canina* L. fruits. *J Ethnopharmacol*, 112: 394-400.
- Ottu OJ, Atawodi SE, Onyike E. 2013. Antioxidant, hepatoprotective and hypolipidemic effects of methanolic root extract of *Cassia singueana* in rats following acute and chronic carbon tetrachloride intoxication. *Asian Pac J Trop Med*, 6: 609-615.
- Pareek A, Godavarthi A, Issarani R, Nagori BP. 2013. Antioxidant and hepatoprotective activity of *Fagonia schweinfurthii* (Hadidi) Hadidi extract in carbon tetrachloride induced hepatotoxicity in HepG2 cell line and rats. *J Ethnopharmacol*, 150: 973-981.
- Ravikumar S and Gnanadesigan M. 2012. Hepatoprotective and Antioxidant Properties of *Rhizophora mucronata* Mangrove Plant in CCl<sub>4</sub> Intoxicated Rats. *J Exp Clin Med*, 4: 66-72.
- Roman I, Stănilă A, Stănilă S. 2013. Bioactive compounds and antioxidant activity of *Rosa canina* L. biotypes from spontaneous flora of Transylvania. *Chem Cent J*, 7: 73.
- Sadeghi H, Zarezade V, Sadeghi H, Akbartabar Toori M, Jafari Barmak M, Azizi A, Ghavamizadeh M, Mostafazadeh M. 2014. Anti-inflammatory Activity of *Stachys Ptilifera* Benth. *Iran Red Crescent Med J*, 16: 9.
- Sathesh Kumar S<sup>1</sup>, Ravi Kumar B, Krishna Mohan G. 2009. Hepatoprotective effect of *Trichosanthes cucumerina* Var *cucumerina* L. on carbon tetrachloride induced liver damage in rats. *J Ethnopharmacol*, 123: 347-350.

- Serteser A, Kargioğlu M, Gök V, Bağcı Y, Ozcan MM, Arslan D. 2009. Antioxidant properties of some plants growing wild in Turkey. *Int J Food Sci Nutr*, 60: 147-154.
- Sharma JB, Sharma A, Bahadur A, Vimala N, Satyam A, Mittal S. 2006. Oxidative stress markers and antioxidant levels in normal pregnancy and pre-eclampsia. *Int J Gynaecol Obstet*, 94: 23-27.
- Srivastava A and Shivanandappa T. 2006. Hepatoprotective effect of the aqueous extract of the roots of *Decalepis hamiltonii* against ethanol-induced oxidative stress in rats. *Hepatol Res*, 35: 267-275.
- Swarnalatha L and Reddy P.N. 2012. Hepatoprotective activity of *Sphaeranthus amaranthoides* on D-galactosamine induced hepatitis in albino rats. *Asian Pac J Trop Biomed* 2: S1900-S1905.
- Wenzig EM, Widowitz U, Kunert O, Chrubasik S, Bucar F, Knauder E, Bauer R. 2008. Phytochemical composition and in vitro pharmacological activity of two rose hip (*Rosa canina* L.) preparations. *Phytomedicine*, 15: 826-835.
- Wu Y, Yang L, Wang F, Wu X, Zhou C, Shi S, Mo J, Zhao Y. 2007. Hepatoprotective and antioxidative effects of total phenolics from *Laggera pterodonta* on chemical-induced injury in primary cultured neonatal rat hepatocytes. *Food Chem Toxicol*, 45: 1349-1355.
- Yang L, Wang CZ, Ye JZ, Li HT. 2011. Hepatoprotective effects of polyphenols from *Ginkgo biloba* L. leaves on CCl<sub>4</sub>-induced hepatotoxicity in rats. *Fitoterapia*, 82: 834-840.
- Zdarilová A, Svobodová A, Simánek V, Ulrichová J. 2009. *Prunella vulgaris* extract and rosmarinic acid suppress lipopolysaccharide-induced alteration in human gingival fibroblasts. *Toxicol In Vitro*, 23: 386-392.