

Original Research Paper

## Effect of hydroalcoholic extract of *ginger* on the liver of epileptic female rats treated with lamotrigine

Ameneh Poorrostami<sup>1\*</sup>, Farah Farokhi<sup>1</sup>, Reza Heidari<sup>1</sup>

<sup>1</sup>Department of Biology, Faculty of science, Urmia university, I. R. Iran

**Article history:**

Received: Jul 8, 2013

Received in revised form:

Aug 28, 2013

Accepted: Sep 17, 2013

Vol. 4, No. 4, Jul-Aug 2014,

276-286.

**\* Corresponding Author:**

Tel: 09364681308

Fax: 04412753172

a.poorrostam@yahoo.com

**Keywords:**

Epilepsy

Lamotrigine

Liver

*Zingiber officinale*

Rat

**Abstract**

**Objective:** Lamotrigine is an antiepileptic drug, widely used in the treatment of epilepsy; long-term use of this drug can cause hepatotoxicity. *Zingiber officinale* Roscoe (*ginger*) possesses antioxidant properties. In present research, the effect of hydroalcoholic extract of *ginger* (HEG) on the liver of lamotrigine-treated epileptic rats was investigated

**Material and Methods:** Forty-eight female Wistar rats were selected and allocated to 8 groups of 6 each. Group 1: Negative controls were treated with normal saline. Group 2: Positive controls were treated with lamotrigine (LTG) (10 mg/kg) daily by gavages for 4 consecutive weeks. Epilepsy was induced in treatment groups by i.p. injection of pentylenetetrazol (PTZ) (40 mg/kg). Group 3: Epileptic group received normal saline (10 ml/kg). Group 4: Epileptic group was treated with LTG (10 mg/kg). Groups 5 and 6: Epileptic groups received HEG (50 and 100 mg/kg). Groups 7 and 8: Epileptic groups received LTG and HEG (50 and 100 mg/kg). At the end of 28 days, blood samples were drawn and their livers were processed for light microscopy.

**Results:** The mean values of TG, CHOL, AST, and ALT activity significantly rose ( $p < 0.01$ ) in groups 2, 3, and 4, while in rats treated with HEG (groups 5, 6, 7, and 8), the levels of liver enzymes significantly decreased ( $p < 0.05$ ) compared with epileptic group treated with lamotrigine (group 4). Histopathological changes of liver samples were comparable with respective control.

**Conclusion:** These results suggest that hydroalcoholic extract of *ginger* improves liver function in lamotrigine-induced hepatotoxicity.

Please cite this paper as:

Poorrostami A, Farokhi F, Heidari R. Effect of hydroalcoholic extract of *ginger* on the liver of epileptic female rats treated with lamotrigine. Avicenna J Phytomed, 2014; 2014; 4 (4): 276-286.

**Introduction**

Chemical kindling is an experimental model of epilepsy and epileptogenesis in which repeated application of initially subconvulsive chemical stimulation induces

progressive seizure activity (Mason and Cooper, 1972).

Pentylenetetrazol (PTZ)-induced kindling is associated with a variety of behavioral, neurophysiological, and neurochemical

## Effect of hydroalcoholic extract of *ginger* on epileptic female rats

alterations resulting in long-lasting changes in hippocampal and cortical glutamate receptor density (Schröder et al., 1993).

Lamotrigine (LTG) is antiepileptic drug, widely used in the treatment of epilepsy and bipolar disorder. It is a phenyl triazine derivative and its mechanism of action is related to the blockade of voltage-dependent sodium channels which stabilises presynaptic membranes and inhibits excitatory neurotransmitter release (Messenheimer, 1995). Patients receiving chronic treatment with lamotrigine in the form of single or polytherapy are at a high risk of developing signs and symptoms of drug toxicity. A case of fatal progressive hepatotoxicity in a patient treated with LTG was reported (Leach et al., 1986; Overstreet et al., 2002). Liver is vulnerable to drug-induced toxicity mainly because of its role as a primary organ of drug elimination and its subsequent exposure to potential toxins. Many commonly prescribed medications including virtually all of the major antiepileptic drugs can cause hepatotoxicity. Hepatic reactions to LTG ranged from transient elevation of hepatic enzymes without clinical signs or symptoms of hepatic dysfunctions to fatal hepatotoxicity (Overstreet et al., 2002; Meshkibaf et al., 1995; Betts et al., 1991).

Oxidative stress, resulting from an imbalance in the generation of free radicals and antioxidant defense molecules, affects biological macromolecules causing their structural alterations that lead to cell damage and its death (Ryter et al., 2007). Long-term use of certain antiepileptic drugs has also been shown to increase oxidative stress (Maertens et al., 1995). The most important effect of free radicals is lipid peroxidation, which causes disruption of cell membrane thereby leading to their destruction (Barber and Bernheim, 1967). It is reported that free radical generation due to the increased activity of the glutamatergic transmitter plays a crucial role in neuronal cell death of the

PTZ kindling in rats (Rocha et al., 1996; Schroder et al., 1993; Sechi et al., 1997; Sejima et al., 1997; Rauca et al., 1999; Becker et al., 1997).

Botanical medicines have been used traditionally by herbalists and indigenous healers worldwide for the prevention and treatment of liver disease (Takeoka and Dao, 2003). *Ginger* is gaining popularity amongst modern physicians and its underground rhizomes are the medicinally useful part (Mascolo et al., 1989). The important active components of the *ginger* root are thought to be volatile oils and pungent phenol compounds such as gingerols, shogaols, zingerone, and gingerols (Sekiwa et al., 2000; Zancer et al., 2002). The pharmacological effects of *ginger* and its pungent constituents, fresh and dried rhizome were investigated. Among the demonstrated effects, anti-platelet, antioxidant, anti-tumor, antirhinoviral, anti-hepatotoxicity, anti-arthritic, and antidiabetic effects can be mentioned (Fisher-Rasmussen et al., 1991; Sharma et al., 1994; Kamtchoving et al., 2002; Islam and Choi, 2008).

*Ginger* was found to have hypocholesterolemic effects and causes decrease in body weight, glucose in blood, serum total cholesterol, and serum alkaline phosphatase in adult male rats (Bhandari et al., 2005). *Ginger* extract attenuated, in a dose-dependent manner, CCl<sub>4</sub> and acetaminophen-induced increases in the activities of ALT, AST, and ALP in rats blood (Yemitan and Izegebu, 2006). Other investigators have also shown the hypolipidemic effect of *ginger* (sharma et al., 1996). Akhiani et al. (2004) reported that *ginger* treatment significantly decrease both serum cholesterol and triglycerides. The study of Gujaral revealed that serum and liver cholesterol decreased when *ginger* was administered to hypercholesterolemic rats (Gujaral et al., 1978). Gingerol inhibited lipid peroxidation induced by FeCl<sub>3</sub>-ascorbate

system (Aeschbach *et al.*, 1994). Gingerol inhibited the oxidative activity of xanthine which generated reactive oxygen species (ROS), for example superoxide anions (Chang *et al.*, 1994). In this research, protective effect of hydroalcoholic extract of *ginger* against lamotrigine-induced hepatotoxicity was investigated.

## Materials and Methods

### Plant materials

The *ginger* rhizomes (*Z. officinale*) was purchased from the local market and identified by a professor from the Department of Biology at Urmia University with herbarium number of 4G041. The rhizomes was peeled, chopped into tiny bits, air-dried for 2 weeks, and ground with a mechanical grinder. The ground plant (500 g) was macerated in 70% ethanol for 48 h, filtered with a white cloth and the filtrate was concentrated using a rotary evaporator at an optimum temperature of 40-50 °C (Anosike *et al.*, 2009). The dried yield of the extract was 5 g.

### Experimental animals

Forty-eight adult female rats weighing 200-230 g (obtained from the Pasteur Institute central animal house, Tehran, Iran) were used for the study. They were fed with standard diet pellets and allowed food and water *ad-libitum* for an acclimation period of 4 weeks. The animals were maintained in a strictly controlled temperature (22-25 °C). Twelve hours of light and dark cycles were followed in a fully ventilated room.

### PTZ kindling

Over a period of 20 days, animals were injected intraperitoneally with subconvulsive doses of PTZ (40 mg/kg) in saline every 48 h. After each injection, the convulsive behavior was observed for 30 min, and antiseizure results were scored as follows: stage 0, no response; stage 1, ear and facial

twitching; stage 2, convulsive waves axially through the body; stage 3, myoclonic jerks and rearing; stage 4, clonic convulsions with the animal falling on its side; and stage 5, repeated severe tonic-clonic convulsions or lethal convulsions. The animals were considered to be kindled after having received 10 PTZ injections and reached at least three consecutive stage 4 or stage 5 seizures (Becker *et al.*, 1995).

### Chemicals

Pentylentetrazole was obtained from sigma chemicals company, Germany. Kits of ALT, AST, cholesterol, and triglycerides were purchased from ZiestChem Diagnostics, Tehran, Iran. Lamotrigine was obtained from BakhtarBioshimicompany (Tehran, Iran).

### Experimental protocol

The experimental animals were divided into 8 groups, each group contained 6 animals: Group 1: Negative controls were treated with normal saline (C1). Group 2: Positive controls were treated with LTG (10 mg/kg) daily by gavages for 4 consecutive weeks (CL2). Epilepsy was induced in treatment groups by i.p. injection of PTZ (40 mg/kg). Group 3: Epileptic group received normal saline (10 ml/kg) (CP3). Group 4: Epileptic group were treated with LTG (10 mg/kg) (LP4). Groups 5 and 6: Epileptic groups (PG5, PG6) received HEG (50 and 100 mg/kg, respectively). Groups 7 and 8: Epileptic groups (LPG7, LPG8) received LTG and HEG (50 and 100 mg/kg, respectively) daily by gavages for 4 weeks.

### Preparation of liver homogenate

At the end of study, livers were immediately removed and weighed. Each liver was cut longitudinally into two halves; one half was fixed in 10% phosphate-buffered formalin for histological examination, while the other half was stored at -70 °C for biochemical analysis (Magda *et al.*, 2011).

### Catalase (CAT) activity measurement

Catalase activity was measured following the method of Aebi (1984) Phosphate buffer (0.50 mM, pH 7.0) and 30% H<sub>2</sub>O<sub>2</sub> were freshly prepared. Two ml of sample solution was mixed with 1 ml of H<sub>2</sub>O<sub>2</sub>, and the decomposition of hydrogen peroxide was measured spectrophotometrically at 240 nm against a blank containing 2 ml of sample solution and 1 ml of phosphate buffer. To avoid the intervention by bubbling, the reaction time was controlled by not exceeding 30 seconds.

### Determination of lipid peroxidation (MDA)

Liver lipid peroxidation was determined by the formation of thiobarbituric acid reactive substances (TBARS) according to the method of Ledwozyw et al. (1986). Malondialdehyde (MDA) is formed as an end product of lipid peroxidation which reacts with TBA reagent under acidic condition to generate a pink colored product. Liver suspension (0.1 ml) was added to 0.4 ml of distilled water, followed by the addition of 2.5 ml of trichloroacetic acid (TCA) and left at room temperature for 15 minutes. TBA (1.5 ml) was then added and heated in a water bath at 100 °C for 30 minutes until a faint pink color was obtained. After cooling, the color was extracted in 1 ml of butanol and the intensity was measured using the spectrophotometer at 535 nm.

### Statistical analysis

All values were expressed as mean±SEM and the differences were compared using (ANOVA) followed by Tukey's multiple comparison tests. For all analyses, p<0.05 were considered significant.

## Results

### Histological Findings

Histological studies of control animals showed normal hepatocytes with normal

storage of carbohydrates (Figure 1). (C1) The liver section of LTG treated animals (Group 2) (CL2) showed extension of central vein, hepatocyte necrosis around central vein, and decrease in carbohydrates, whereas the liver section of PTZ-treated animals (Group 3) (CP3) showed intense centrilobular, necrosis and vacuolization and decreased storage of carbohydrates.

The livers of animals treated with PTZ and LTG (Group 4) (LP4) showed congestion of central vein, hepatocyte necrosis, presence of white blood cells (WBC), and decrease in carbohydrates. The animals treated with different doses of HEG showed recovering of hepatocyte, especially in the 100 mg/kg group, with minimal inflammation and near-normal architecture showing higher protective activity as compared with other groups. However, the liver sections of rats on treatment with hydroalcoholic extract of *ginger* exhibited significant liver protection, as evident by the presence of normal hepatic cords, absence of necrosis, and increasing carbohydrates storage, when compared with the standard drug and control animals.

Histological studies of difference epileptic groups treated showed increase storage of carbohydrates (Figure 2). PG5: Liver section of PTZ group treated with hydroalcoholic extract of *ginger* (50 mg/kg) showed increased storage of carbohydrates and extension of central vein. PG6: Specimen obtained from epileptic groups treated with HEG (100 mg/kg), showed increased storage of carbohydrates compared with LP group and presence of white blood cells (WBC) in sinusoids. LPG7: Liver section of epileptic groups treated with lamotrigine and HEG (50 mg/kg) demonstrated increased storage of carbohydrates and extension of central vein compared with PG5. LPG8: Liver section of epileptic groups treated with lamotrigine and HEG (100 mg/kg) exhibited increased storage of carbohydrates with normal central vein (CV) and hepatocyte cells.



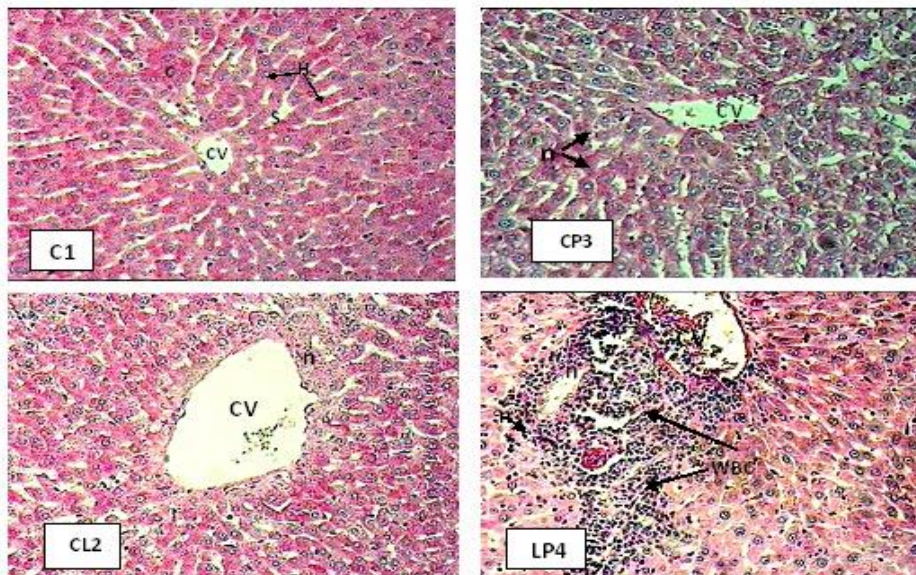


Figure 1. The effects of lamotrigine and PTZ on hepatic tissues of rats stained with Periodic Acid Schiff (PAS,  $\times 400$ ). Normal central vein (CV), Hepatocyte cells (H), sinusoids (S), carbohydrates (C), Hepatocyte necrosis (n), white blood cells (WBC).

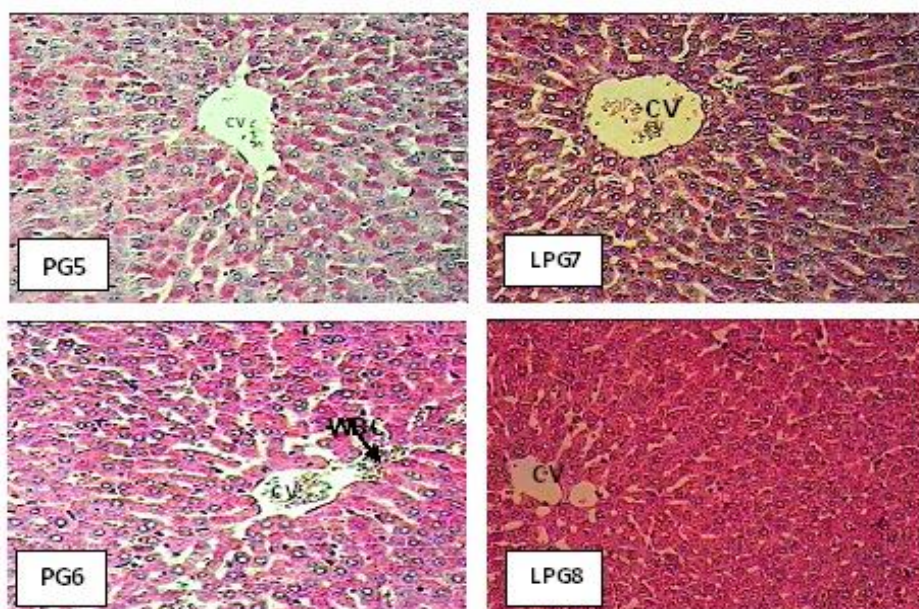


Figure 2. The effects of lamotrigine, PTZ, and *ginger* on rats hepatic tissue stained with Periodic Acid Schiff (PAS,  $\times 400$ ). Normal central vein (CV), white blood cells (WBC).

### Biochemical findings

Table 1 shows that the mean values of liver enzymes (ALT and AST) in all of the experimental groups of rats were significantly increased when compared with normal rats (C1). Treatment of the epileptic

rats with 100 mg/kg HEG (PG6 and LPG8) caused a significant reduction in the serum ALT and AST ( $p < 0.05$ ) when compared with epileptic group treated with lamotrigine.

Similarly, the serum cholesterol and triglyceride levels were significantly higher

## Effect of hydroalcoholic extract of *ginger* on epileptic female rats

in all of the experimental groups compared with normal rats (C1). However, treatment of the epileptic rats with 100 mg/kg HEG (PG6 and LPG8) caused a significant reduction in the serum cholesterol and triglyceride levels ( $p < 0.05$ ) when compared with epileptic group treated with lamotrigine. Table 2 shows that the mean value of malondialdehyde in all the experimental groups of rats was significantly increased when compared with normal rats (C1). The obtained results in this research showed that malondialdehyde levels were significantly

raised in epileptic rats (Group 3) ( $p < 0.01$ ) as compared with the negative control rats. Treatment of the epileptic rats with 100 mg/kg HEG (PG6 and LPG8) caused a significant reduction in MDA level ( $p < 0.05$ ) when compared with epileptic group treated with lamotrigine.

Treatment of the epileptic rats with 100 mg/kg HEG (PG6 and LPG8) caused a significant increase in CAT activity ( $p < 0.05$ ) when compared with epileptic group treated with lamotrigine.

Table 1. Serum levels of liver enzymes and plasma lipids profile of the experimental groups

Groups	C <sub>1</sub>	CL <sub>2</sub>	CP <sub>3</sub>	LP <sub>4</sub>	PG <sub>5</sub>	PG <sub>6</sub>	LPG <sub>7</sub>	LPG <sub>8</sub>
<b>ALT(U/L) mean ±SEM</b>	31.53±0.46	66.49±0.45 **	64.52 ±0.26 **	73.1±0.17 **	62.4±0.36 +	56.01±0.41 +	60.1±0.15 +	54.4±0.35 +
<b>AST(U/L) mean ±SEM</b>	84.13±0.41	118.52±0.54 **	116.06±0.4 **	120.29±0.67 **	101.13±0.19 +	97.35±0.5 +	98.79±0.38 +	93.69±0.51 +
<b>Cholesterol (mg/dl) mean ±SEM</b>	111.26±0.4	134.3±0.34 **	132.20±0.37 **	136.3±0.32 **	128.76±0.2 +	123.35±0.23 +	126.6±0.3 +	119.27±0.3 +
<b>Triglyceride (mg/dl) mean ±SEM</b>	70.77±0.42	124.58±0.34 **	117.08±0.19 **	130.25±0.51 **	86.61±0.55 +	82.52±0.26 +	84.67±0.36 +	80.54±0.27 +

Values are expressed as mean±SEM, n=8. Statistical difference between different experimental groups vs. negative control (Group 1) \*\*:  $p < 0.01$ ; Statistical difference between different experimental groups vs. epileptic group treated with lamotrigine (Group 4) +:  $p < 0.05$ . C1: Negative control, CL2: Positive control, CP3: PTZ control, LP4: LTG+PTZ, PG5: PTZ+HEG50, PG6: PTZ+HEG100, LPG7: LTG+PTZ+HEG50, LPG8: LTG+PTZ+HEG100.

Table 2. Levels of malondialdehyde and catalase in liver tissue of the experimental groups

Groups	C <sub>1</sub>	CL <sub>2</sub>	CP <sub>3</sub>	LP <sub>4</sub>	PG <sub>5</sub>	PG <sub>6</sub>	LPG <sub>7</sub>	LPG <sub>8</sub>
<b>MDA(n mol/g tissue) mean ±SEM</b>	30.7±1.08	59.03±0.15 **	56.23±0.67 **	63.83±0.8 **	52.53±0.38 +	46.6±0.47 +	50.23±0.5 +	41.06±1.03 +
<b>CAT(U/mg protein) mean ±SEM</b>	146.8±0.85	84.2±0.55 **	89.2±0.15 **	80.6±0.62 **	111.06±1.56 +	128.53±0.49 +	116.06±0.86 +	131.03±1.28 +

Values are expressed as mean±SEM, n=8. Statistical difference between different experimental groups vs. negative control (Group 1) \*\*:  $p < 0.01$ ; Statistical difference between different experimental groups vs. epileptic group treated with lamotrigine (Group 4) +:  $p < 0.05$ . C1: Negative control, CL2: Positive control, CP3: PTZ control, LP4: LTG+PTZ, PG5: PTZ+HEG50, PG6: PTZ+HEG100, LPG7: LTG+PTZ+HEG50, LPG8: LTG+PTZ+HEG100.

## Discussion

Liver is the main organ responsible for drug metabolism and appears to be the sensitive target site for substances modulating biotransformation (Gram and Gillette, 1971). Clinical sequelae of hepatic failure in a patient treated with lamotrigine were reported. The liver damage was documented in serial liver biopsies, which showed approximately 50% hepatocyte necrosis (Overstreet *et al.*, 2002). In this research liver section of rats treated with lamotrigine showed extension of central vein, decreased storage of carbohydrates, and hepatocyte necrosis.

Specific reason to question a causal relationship between LTG therapy and hepatotoxicity was provided by a recent study in which a cohort study conducted by means of prescription-event monitoring (PEM) reported LTG to be safe when used for refractory epilepsy but there were individual cases of hepatotoxicity (Mackay *et al.*, 1997). The mechanism of lamotrigine-induced liver failure that occurred is not clearly understood. Previous reports have attributed this reaction to an immune-mediated allergic reaction (Fayad *et al.*, 2000; Mecarelli *et al.*, 2005; Overstreet *et al.*, 2002; Sauve *et al.*, 2000). Histopathological findings in this research revealed the presence of white blood cells (WBC) around central vein in Group 4 (Figure 1, LP4).

Free radicals and reactive oxygen species (ROS) are continuously produced in the body. These oxygen species are the cause of cell damage and the progression of tumor cells to cancer cells. Therefore, tissues must be protected from oxidative injury through intracellular (SOD, GPx, and catalase) as well as extracellular (vitamins, micronutrients, and antioxidants originated from herbs) antioxidants (Halliwell and Gutteridge, 1999). Oxygen free radicals are mostly removed by endogenous antioxidants such as superoxide dismutase (SOD),

glutathione peroxidase (GPx), and catalase (Das, 2002). Lipid peroxidation could change the properties of biological membranes, resulting in severe cell damage and thus play a significant role in the pathogenesis of diseases. It has been shown that certain lipid peroxidation products induce fibrogenic cytokines and increase the synthesis of collagen (Mi-Ok and Jeon-Ok, 2010).

The oxidative damage in tissue can be limited by exogenous antioxidants. The most important defenses are enzymatic antioxidants, such as SOD, CAT, and non-enzymatic antioxidants as GSH (Wang *et al.*, 2004). SOD, a manganese-containing enzyme is the first antioxidant enzyme to deal with oxyradicals by accelerating the dismutation of superoxide to hydrogen peroxide, while CAT is a peroxisomal hemeprotein that catalyzes the removal of hydrogen peroxide formed during the reaction catalyzed by SOD (Weydert *et al.*, 2006). Catalase is an enzyme responsible for detoxification of H<sub>2</sub>O<sub>2</sub> formed by the action of superoxide dismutase. The process of epileptogenesis and long-term use of certain antiepileptic drugs has been shown in previous studies to cause increase in reactive oxygen species leading to oxidative stress and neuronal damage in patients with epilepsy. The activity of the enzyme catalase has been shown to decline in epileptic patients (Sudha *et al.*, 2001).

The obtained results in this research indicated that in epileptic rats (Group 3) the catalase activities decreased ( $p < 0.01$ ) when compared with negative control group. The malondialdehyde assay is often considered as an index of free radical generation which increases in conditions of oxidative stress (Kehrer, 1993). The obtained results from this research showed that the mean value of malondialdehyde levels were significantly raised in treated rats with LTG and PTZ (Table 2). These results confirm the observations of previous studies which had

## Effect of hydroalcoholic extract of *ginger* on epileptic female rats

shown increased lipid peroxidation in pentylenetetrazole-induced kindling in rats (Rauca et al., 1999).

Previous studies indicated that the administration of aqueous extract of *ginger* to rats, orally and intraperitoneally, at two different levels of doses, significantly decreased the activities of some serum enzymes such as aspartate aminotransaminase (AST) and alanine aminotransaminase (ALT) (Alnaqeeb et al., 2003). *Ginger* and silymarin reduced serum ALT, AST, and ALP indicating membrane stabilization and antioxidant properties of *ginger* (Bhandari et al., 2003). Results obtained in the present study revealed that the values of serum AST and ALT were significantly decreased in rats treated with LTG and *ginger* 100 mg compared with epileptic group treated with lamotrigine. Histopathological changes of liver in these groups were improved and storage of carbohydrates was increased.

This indicated the effectiveness of *ginger* in prevention of LTG hepatotoxicity. The mechanism of hepatic injury may be due to inflammatory process so the hepatoprotective activity of *ginger* may be due to its content of volatile oils, which showed anti-inflammatory, analgesic, and immunomodulatory effects. Volatile oil of *ginger* is capable of inhibiting T lymphocyte-dependent immune reactions (Zhou et al., 2006)

The effect of the ethanol extract of the rhizome of *Z. officinale* was tested against carbon tetrachloride and acetaminophen-induced liver toxicities in rats. CCl<sub>4</sub> and acetaminophen induced many histopathological changes and increased the activities of ALT, AST, ALP, LDH, and SDH in the blood serum. *Ginger* extract was found to have a protective effect against CCl<sub>4</sub> and acetaminophen-induced damage as confirmed by histopathological examination of the liver (Yemitan and Izegbu, 2006).

Chang et al., found the bioactive component of *ginger*, namely gingerol, possessed antioxidative effect by inhibiting peroxidation of phospholipids induced by xanthine oxidase activity. Amin and Hamza demonstrated that *Z. officinal* increased the activities of testicular antioxidant enzymes, superoxide dismutase, glutathione, and catalase and reduced level of malondialdehyde. In this research, treating epileptic animals with LTG+*ginger* (100 mg/kg, Group 8) induced a significant decrease in the malondialdehyde which is lipid peroxidation marker and a significant increase in the level of serum antioxidant enzyme. Siddaraju and Dharmesh reported that *ginger*-free phenolic and *ginger*hydrolysed phenolic fractions exhibited free radical scavenging, inhibition of lipid peroxidation, DNA protection, and reducing power abilities indicating strong antioxidant properties.

Anti-inflammatory activity of *ginger* is due to the presence of gingerols which have the ability to inhibit prostaglandins and leukotriene synthesis, (Nurtjahja et al., 2003). In the present study, treating epileptic animals with *ginger* extract (100 mg/kg, Group 8) induced a significant decrease in cholesterol and triglycerides levels. These findings are in agreement with previous studies that treatment with *ginger* juice significantly decreased triglycerides and cholesterol levels in diabetic rats. Reduction in serum lipid levels with *ginger* might be due to its antagonistic action on streptozotocin receptors, thereby increasing insulin levels (Akhani et al., 2004). The ethanolic extract of *ginger* significantly reduced serum total cholesterol and triglycerides and increased the HDL-cholesterol levels (Bhandari et al., 2005). Hypolipidemic and anti-atherosclerotic effects of *ginger* extract were also demonstrated in cholesterol-fed rabbits (Bhandari and Grover, 1998). It was



concluded that the hypocholesterolemic effect of *ginger* could have possibly resulted from the inhibition of cellular cholesterol biosynthesis after the consumption of the extract (Fuhrman et al., 2000).

Hydroalcoholic extract of *ginger* protects liver tissue from lipid peroxidation and exhibits a significant lipid lowering activity in epileptic rats.

### Acknowledgement

The authors gratefully acknowledge the financial assistance of the Urmia University in performing this investigation. The authors declare that there are no conflicts of interest in this study.

### Conflict of interest

There is not any conflict of interest in this study.

### References

- Aebi H. 1984. Methods of Enzymatic Analysis. Catalase. In: Bergmayer HU eds. London: Academic press, pp. 671-684.
- Aeschbach R, Loliger J, Scott BC, Murcia A, Butler B, Halliwell B, Aruoma OI. 1994. Antioxidant actions of thymol, carbacrol, 6-gingerol, zingerone and hydroxytyrosol. Food Chem Toxicol, 32: 31-36.
- Akhani SP, Vishwakarma SL, Goyal RK. 2004. Anti-diabetic activity of *Z. officinale* in Streptozotocin-induced type I diabetic rats. J Pharm Pharmacol, 56: 101-105.
- Alnaqeeb MA, Thomson M, Al-qattan KK, Kamel AF, Mustafa T, Ali M. 2003. Biochemical and histopathological toxicity of an aqueous extract of *ginger* in female rats. Kuwait J Sci Eng, 30: 35-48.
- Amin A, Hamza AA. 2006. Effects of Rosell and *ginger* on cisplatin- induced reproductive toxicity in rats. Asian J Androl, 8: 607-612.
- Anosike CA, Obidoa O, Ezeanyika LUS, Nwuba MM. 2009. Anti-inflammatory and anti-ulcerogenic activity of the ethanol extract of *ginger* (*Zingiber officinale*). Afr J Biochem Res, 3: 379-384.
- Barber AA, Bernheim F. 1967. Lipid peroxidation its measurement occurrence and significance in animal tissues. Adv Gerontol, 2: 355-403.
- Becker A, Grecksch G, Schröder H. 1995. *N*-nitro-l-arginine methyl ester interferes with pentylene-tetrazol-induced kindling and has no effect on changes in glutamate binding. Brain Res, 688: 230-232.
- Becker A, Krug M, Schroder H. 1997. Strain differences in pentylene-tetrazole kindling development and subsequent potentiation effects. Brain Res, 763: 87- 92.
- Betts T, Goodwin G, Withers RM, Yuen AW. 1991. Human safety of lamotrigine. Epilepsia, 32: 17-21.
- Bhandari U, Grover JK. 1998. Effect of ethanolic extract of *ginger* on hyperglycemic rats. Int J Diabet, 6: 95-96.
- Bhandari U, Shamsher A, Pillai KK. 2003. Antihepatotoxic activity of *Ginger* Ethanol Extract in Rats. Pharm Biol, 41: 66-71.
- Bhandari U, Kanojia R, Pillai KK. 2005. Effect of ethanolic extract of *Zingiber officinale* on dyslipidaemia in diabetic rats. J Ethnopharmacol, 97: 227-230.
- Chang WS, Chang YH, Lu FJ, Chiang HC. 1994. Inhibitory effects of phenolics on xanthine oxidase. Anticancer Res, 14: 501-506.
- Das UN. 2002. A radical approach to cancer. Med Sci Monit, 8: RA79-82.
- Fayad M, Choueiri R, Mikati M. 2000. Potential hepatotoxicity of lamotrigine. Pediatr Neurol, 22: 49-52
- Fisher- Rasmussen W, Kjaer SK, Dahl C, Asping U. 1991. *Ginger* treatment of hyperemesis gravidarum. Eur J Obstet Gynecol Reprod Biol, 38: 19-24.
- Fuhrman B, Roseblate M, Hayek T, Coleman R, Aviram M. 2000. *Ginger* Extract Consumption Reduces Plasma Cholesterol, Inhibits LDL Oxidation and Attenuates Development of Atherosclerosis in Atherosclerotic, Apolipoprotein E-Deficient Mice. J Nutr, 130: 1124-1131.
- Gram TE, Gillette JR. 1971. Biotransformation of drugs. In: Bacq., Z.M (Ed.), Fundamentals of Biochemical Pharmacology. New York: Pergamon Press; p.571-609.
- Gujaral S, Bhumra H, Swaroop M. 1978. Effect of *ginger* oleoresin on serum and hepatic

## Effect of hydroalcoholic extract of ginger on epileptic female rats

- cholesterol levels in cholesterol-fed rats. *Nutr Rep Int*, 17: 183-187.
- Halliwell B, Gutteridge J. 1999. *Free Radicals in Biology and Medicine*. Oxford: Oxford Univ.
- Islam MS, Choi H. 2008. Comparative effects of dietary ginger (*Zingiber officinale*) and garlic (*Allium sativum*) investigated in a type 2 diabetes model of rats. *J Med Food*, 11: 152-159.
- Kamtchoung P, Fndio GY, Dimo T, Jatsa HB. 2002. Evaluation of androgenic activity of *Zingiber officinale* and *Pentadiplandrabrazeana* in male rats. *Asian J Androl*, 4: 299-301.
- Kehrer JP. 1993. Free radical as mediator of tissue injury and disease. *Crit Rev Toxicol*, 23: 21-48.
- Leach M, Harden CM, Millar AA. 1986. Pharmacological studies of lamotrigine, a novel potential antiepileptic drug, II: Neurochemical studies on the mechanisms of action. *Epilepsia*, 27: 490-497.
- Ledwozyw A, Michalak J, Stepian A, Kadziolka A. 1986. The relationship between plasma TG, cholesterol, total lipid peroxidation product during human atherosclerosis. *Clin Chim Acta*, 155: 272-284.
- Mackay FJ, Wilton LV, Pearce GL, Freemantle SN, Mann RD. 1997. Safety of long-term lamotrigine in epilepsy. *Epilepsia*, 38: 881-6.
- Maertens P, Dyken P, Graf W, Pippenger C, Chronister R, Shah A. 1995. Free radicals, anticonvulsants and the neuronal ceroidlipofuscinoses. *Am J Med Genet*, 7: 225-228.
- Magda KE, Germine MH, Rasha MAE. 2011. The Synergistic Hepatoprotective Effect of Curcumina and *Ginger* Against Carbon Tetrachloride Induced- Liver Fibrosis in Rats. *Aust J Basic Appl Sci*, 5: 1962-1971.
- Mascolo N, Jain R, Tain SC, Capasso FJ. 1989. Ethnopharmacologic investigation of ginger (*Zingiber officinale*). *J Ethnopharmacol*, 27: 129-140.
- Mason CR, Cooper RM. 1972. A permanent change in convulsive threshold in normal and brain-damaged rats with repeated small doses of pentylenetetrazol. *Epilepsia*, 13: 663-674.
- Mecarelli O, Pulitano P, Mingoia M, Ferretti G, Rossi M, Berloco PB, Muda AO. 2005. Acute hepatitis associated with lamotrigine and managed with the molecular adsorbents recirculating system (MARS). *Epilepsia*, 46: 1687-1689.
- Messenheimer JA. 1995. Lamotrigine. *Epilepsia*, 36: S87-S94.
- Meshkibaf MH, Subhash MN, Rama Rao BSS, Narayanan CP, Kailashnath KM. 1995. Comparative effect of single and poly therapy on liver enzymes in epileptic patients under long term treatment. *NIMHANS J*, 13: 141-146.
- Mi-Ok S, Jeon-Ok M. 2010. Effect of dietary supplementation of grape skin and seeds on liver fibrosis induced by dimethyl-nitrosamine in rats. *Nutr Res Pract*, 4: 369-374.
- Nurtjahja T, Ammit A, Roufogalis B, Tran V, Duke C. 2003. Effective anti-platelet and COX-1 enzyme inhibitor from pungent constituents of ginger. *Trombo Res*, 111: 259-265.
- Overstreet K, Costanza C, Behling C, Hassanin T, Masliah E. 2002. Fatal progressive hepatic necrosis associated with lamotrigine treatment: A case report and literature review. *Dig Dis Sci*, 47: 1921-1925.
- Rauca C, Zerbe R, Jantze H. 1999. Formation of free hydroxyl radicals after pentylenetetrazole-induced seizures and kindling. *Brain Res*, 847: 347-351.
- Rocha L, Briones M, Ackermann RF, Anton B, Maidment NT, Evans CJ, Engel J. 1996. Pentylenetetrazole-induced kindling: early involvement of excitatory and inhibitory systems. *Epilepsy Res*, 26: 105-113.
- Ryter SW, Kim HP, Hoetzel A, Park JW, Nakahira K, Wang X, Choi AM. 2007. Mechanisms of cell death in oxidative stress. *Antioxid Redox Signal*, 9: 49-89.
- Sauve G, Bresson-Hadni S, Prost P, Le Calvez S, Becker MC, Galmiche J, Carbillet JP, Miguet JP. 2000. Acute hepatitis after lamotrigine administration. *Dig Dis Sci*, 45: 1874-1877.
- Schröder H, Becker A, Lössner B. 1993. Glutamate binding to brain membranes is increased in pentylenetetrazol kindled rats. *J Neurochem*, 60: 1007-1011.
- Sechi G, Rosati G, Deiana GA, Petrucci V, Deriu F, Correddu P, De-Riu PL. 1997. Co-variation of free amino acids in brain

- interstitial fluid during pentylenetetrazole-induced status epilepticus. *Brain Res*, 746: 230-236.
- Sejima H, Ito M, Kishi K, Tsuda H, Shiraishi H. 1997. Regional excitatory and inhibitory amino acid concentrations in pentylenetetrazole kindling and kindled rat brain. *Brain Dev*, 19: 171-175.
- Sekiwa Y, Kubota K, Kobayashi A. 2000. Isolation of novel glucosides related to gingerdiol from *ginger* and their antioxidative activities. *J Agric Food Chem*, 48: 373-377.
- Sharma JN, Srivastava KC, Gan EK. 1994. Suppressive effects of eugenol and *ginger* oil on arthritic rats. *Pharmacol*, 49: 314-318.
- Sharma I, Gusain D, Dixit VP. 1996. Hypolipidemic and antiatherosclerotic effects of *Zingiber officinale* in cholesterol-fed rabbits. *Phyto Res*, 10: 517-518.
- Siddaraju MN, Dharmesh SM. 2007. Inhibition of gastric H<sup>+</sup>, K<sup>+</sup>, ATPase and *Helicobacter pylori* growth by phenolic antioxidants of *Zingiber officinale*. *Mol Nutr Food Res*, 51: 324-332.
- Sudha K, Rao AV, Rao A. 2001. Oxidative stress and anti-oxidants in epilepsy. *Clin Chim Acta*, 303: 19-24.
- Takeoka GR, Dao LT. 2003. Antioxidant constituent of almond [*Prunus dulcis* (Mill.) D.A. Webb.] hulls. *J Agric Food Chem*, 51: 496-501.
- Wang B, Liu C, Tseng C, Wu C, Yu Z. 2004. Hepatoprotective and antioxidant effects of *Bupleurum kaioi* Liu (Chao et Chuang) extract and its fractions fractionated using supercritical CO<sub>2</sub> on CCl<sub>4</sub>-induced liver damage. *Food Chem Toxicol*, 42: 609-617.
- Weydert C, Waugh T, Ritchie J, Iyer K, Smith J, Spitz DR. 2006. Overexpression of manganese or copper-zinc superoxide dismutase inhibits breast cancer growth. *Free Rad Biol Med*, 41: 226-237.
- Yemitan OK, Izegebu MC. 2006. Protective effects of *Zingiber officinale* (Zingiberaceae) against carbon tetrachloride and acetaminophen-induced hepatotoxicity in rats. *Phytother Res*, 20: 997-1002.
- Zancan KC, Marques MO, Petenate AJ, Meireles MA. 2002. Extraction of *ginger* (*Zingiber officinale* Roscoe) oleoresin with CO<sub>2</sub> and cosolvents: A study of the antioxidant action of the extracts. *J Supercrit Flu*, 24: 57-76.
- Zhou H, Deng Y, Xie Q. 2006. The modulatory effects of the volatile oil of *ginger* on the cellular immune response in vitro and in vivo in mice. *J Ethnopharmacol*, 105: 301-305.