

Original Research Article

Toxicological profile of the aqueous-fermented extract of *Musa paradisiaca* in rats

Eziuche Amadike Ugbogu¹, Victor Chibueze Ude^{2*}, Iheanyichukwu Elekwa¹, Uche Okuu Arunsi¹, Chikezie Uche-Ikonne³, Chinedu Nwakanma¹

¹Department of Biochemistry Abia State University, PMB 2000, Uturu, Abia State, Nigeria

²Department of Medical Biochemistry, College of Medicine Enugu State University of Science and Technology, PMB 01660, Enugu-Nigeria

³Federal Medical Centre Umuahia, Abia State, Nigeria

Article history:

Received: Nov 10, 2017

Received in revised form:

Mar 19, 2018

Accepted: Apr 07, 2018

Vol. 8, No. 6, Nov-Dec 2018,
478-487.

*** Corresponding Author:**

Tel: +234(0)8039461045

v.c.ude@esut.edu.ng

victor_chibueze@yahoo.co.uk

Keywords:

Musa Paradisiaca

acute toxicity

Sub-acute toxicity

Haematology

Lipid profile

Histopathology

Abstract

Objective: This study was conducted to assess the toxicity profile of the aqueous-fermented extract of *Musa paradisiaca* in rats.

Materials and Methods: In acute toxicity test, the rats of different groups were orally administered with a single dose of 500, 1000, 2000 and 5000 mg/kg of fermented extract of *M. paradisiaca*. The rats were monitored for behavioral changes, toxicity signs and mortality. In sub-acute test, the rats were orally administered with fermented *M. paradisiaca* extract (200, 400 and 800 mg/kg/day) for 14 days. Haematological and serum biochemical parameters were evaluated and histopathological studies of the liver and kidney were done. The study was performed from June to July 2017.

Results: Concerning the acute toxicity, no toxicity signs or death were recorded and an LD₅₀ value of >5 g/kg for fermented extract of *M. paradisiaca* was observed. Regarding the sub-acute toxicity, ingestion of the fermented extract of *M. paradisiaca* caused no significant effects ($p < 0.05$) in terms of relative organ weight, body weight percentage, haemoglobin, red blood cells count, electrolytes levels, lymphocytes count, basophils count, and aspartate aminotransferase (AST) and alkaline phosphatase (ALP) levels. However, significant differences ($p < 0.05$) were observed in white blood cells, eosinophils, platelets, neutrophils and monocytes counts, and urea, creatinine, alanine aminotransferase (ALT) and high-density lipoprotein (HDL) levels. The histological assessments of the liver and kidney showed normal results.

Conclusion: The findings of this study has suggested that daily administration of fermented extract of *M. paradisiaca* at doses up to 800 mg/kg for 14 days, is not toxic and may be considered safe for therapeutic uses.

Please cite this paper as:

Ugbogu EA, Ude VC, Elekwa I, Arunsi UO, Uche-Ikonne C, Nwakanma C. Toxicological profile of the aqueous-fermented extract of *Musa paradisiaca* in rats. Avicenna J Phytomed, 2018; 8(6): 478-487.

Introduction

Musa paradisiaca (Linn.) (*Musaceae*) is a herbaceous plant which is commonly known as “plantain”. It is indigenous to South Asia and India and is presently grown in almost all tropical and subtropical regions of Africa including Nigeria. This plant grows up to 9 m in length and produces greenish or greenish-yellow seedless oblong fruits of up to 7 cm long in bunch form depending on the variety and the nutrient present in the soil (Dutta et al., 1993; Imam and Akter, 2011; Yakubu et al., 201). The proximate analysis of *M. paradisiaca* revealed the presence of protein, dietary fibre, carbohydrates, lipids, minerals such as potassium (K), magnesium (Mg), phosphorus (P), calcium (Ca), sodium (Na), zinc (Zn) and iron (Fe), and water-soluble vitamins such as thiamine, riboflavin, niacin, ascorbic acid and folic acid (Ketiku 1973; Coulibaly et al., 2007; Eleazu et al., 2011; Ibukun et al., 2012; Adeolu and Enesi, 2013; Danlami et al., 2015; Kiin-Kabari and Giami, 2015; Annor et al., 2016). The bioactive metabolites present in the fruits of plantain include, flavonoids, tannins, alkaloids, glycosides, phytates, oxalates, amino acids, steroids, benzoic acid derivatives, ascorbic acid, and vitamin A (Dutta et al., 1983; Eleazu et al., 2011; Adeolu and Enesi, 2013; Rao et al., 2014; Danlami et al., 2015).

Traditional medicine (TM) is comprised of explicable and inexplicable knowledge, acquired skills, and sometimes beliefs from different cultures of the world which are used in the treatment of diseases and maintenance of good health. TM is also designated as complementary and alternative medicine (CAM) and/or non-conventional medicine in developed countries (Zhang, 2000). In Africa, more than 80 % of the population use TM while in developed countries such as Canada, up to 70% of the population use CAM for their healthcare needs (World Health Organization, 2002) because of its accessibility, affordability, efficacy,

bioavailability and less side effects (Elujoba et al., 2005; Ezekwesili et al., 2014; Elujoba et al., 2005; Ugbogu et al., 2016).

Due to the presence of the several nutrients including minerals and bioactive metabolites in *M. paradisiaca*, virtually all parts of the plant have been used for management of various ailments. For example, aqueous extract of fermented unripe *M. paradisiaca* fruits and unripe *M. paradisiaca* peels possess anti-ulcerogenic (Ezekwesili et al., 2014; Ikpeazu et al., 2017) and anti-microbial (Kapadia et al., 2015) activities. Studies have also shown that aqueous extract of *M. paradisiaca* fruit pulp possesses antioxidant (Shodehinde and Oboh, 2013) and wound healing properties (Agarwal et al., 2009) and could be used as a remedy against diabetes and hepatic dysfunction (Ojewole and Adewunmi, 2003; Eleazu and Okafor, 2015). Extracts of *M. paradisiaca* stem are used for wound healing and have been shown to have antimicrobial activity (Amutha and Selvakumari, 2016) and hepato-protective property (Nirmala et al., 2012). *M. paradisiaca* flower possesses antimicrobial and anti-hyperglycemic (Jawla et al., 2012) as well as anti-diarrhoea effects (Yakubu et al., 2015). Amongst all these potential uses of *M. paradisiaca* for management and treatment of diseases, there is little or no published data on comprehensive assessment of the toxicity of aqueous extract of fermented *M. paradisiaca* which is currently used in treating ulcers. A previous investigation (Ikpeazu et al., 2017) revealed that the effectiveness of fermented products over the non-fermented counterparts is due to the synergistic role of phytoconstituents and microbiomes. Probiotics, as live microorganisms, have been observed to confer health benefits such as enhancement of mineral metabolism, reduction of LDL-C level, stimulation of vitamin B-complex biosynthesis, modulation of the immune system, anti-hypertensive and antiulcerogenic effects (Musa et al., 2009;

Liong *et al.*, 2009; Haukioja, 2010). It is against this backdrop that the current study was designed to assess the toxicity profile of aqueous-fermented extract of *M. paradisiaca* concerning body weight, relative organ weight, and histopathological indices as well as haematological, hepatocellular, and lipid profiles in rats.

Materials and Methods

Sample collection and identifications

Fresh unripe plantain (*M. paradisiaca*) was purchased from Eke Okigwe Market, Okigwe Local Government Area in Imo State. It was authenticated by a Botanist as *Musa paradisiaca*; a sample was kept at the herbarium of University of Nigeria Nsukka with voucher number UNH No.: 812.

Sample preparation

The rotten fruits were removed, and the rest were washed with clean water. *M. paradisiaca* were peeled, washed and cut into approximately 4-mm long pieces. With the aid of G & G® Electronic scale, 200 g of the sliced *M. paradisiaca* were weighed in a beaker and 300 ml of distilled water was added. The beaker containing the plantain and water was covered and allowed to stand at room temperature (25°C), overnight (i.e. from 6 pm to 8 am). After 15 h of fermentation, the extract was filtered using cheesecloth and the filtrate was used immediately.

Animal handling

A total of 74 healthy rats (150-200g) comprising 50 males and 24 female rats were purchased from University of Nigeria Nsukka and transported to Biochemistry Department, Abia State University Uturu, Nigeria. The rats were allowed to acclimatize for two weeks in a well-ventilated house with clean cages under normal environmental conditions of temperature (25-28°C) and humidity (35-60 %) with 12 h/12 h light/dark cycles, before the start of the experiment. The rats were fed with standard commercial food and they

had free access to water. Strict adherence to ethical principles (Neuwinger 2000), of the World Health Organization of good laboratory practices and United States guidelines for animal experiments (Care, Animal, and Use Committee, 1998, CNRC, 2010) was maintained in this study. Experimental procedures and animal handling were approved by the Abia State University Research Ethical Clearance Committee -ABSU/REC/BMR/015.

Acute toxicity test (median lethal dose (LD₅₀))

A total of 50 rats were divided into five experimental groups of ten (10) rats and each group consisted of five (5) female and five (5) male rats. The rats were fasted overnight and a single dose of 500, 1000, 2000 or 5000 mg/kg aqueous-fermented extract of *M. paradisiaca* fruit pulp was orally (i.e. gavage) administered to groups B, C, D and E, respectively while group A received 0.25 ml of distilled water and served as the control. The rats were monitored for behavioral changes, toxicity signs and mortality for 24 h and thereafter for 14 days (OECD, 2001) guideline 423 with little modifications.

Sub-acute toxicity study

Twenty-four (24) male rats were allocated into four (4) experimental groups each consisted of six (6) rats. Aqueous-fermented extract of *M. paradisiaca* fruit pulp (200, 400, or 800 mg/kg) or 0.25 ml of distilled water for the control group, were administered once daily for 14 consecutive days (OECD, 1995) guideline 407.

Organs and blood sample collection

After 14-days administration of aqueous-fermented extract of *M. paradisiaca* fruit pulp the rats were anesthetized and sacrificed immediately on the 15th day of the experiment. Blood samples were collected via cardiac puncture. The samples for biochemical tests were dispensed into heparinized containers while the samples for haematological

Toxicological Profile of *Musa paradisiaca*

analysis were collected into ethylenediaminetetraacetic acid (EDTA)-containers. The heart, kidney, liver, lungs and spleen were carefully removed by dissection and their weights were determined.

Haematological studies

The haematological studies were performed as described by Bain et al. (2016). The haematological parameters evaluated were haemoglobin (Hb) level, white blood cell (WBC) count, packed cell volume (PCV), red blood cell (RBC) count, platelet count, mean cell volume (MCV), mean corpuscular haemoglobin (MCH) and mean corpuscular haemoglobin concentration (MCHC).

Clinical chemistry studies

Liver enzymes including alanine aminotransferase (ALT), aspartate aminotransferase (AST) and alkaline phosphatase (ALP); renal function parameters including bicarbonate (HCO_3^-), chloride (Cl^-), creatinine, potassium (K^+), sodium (Na^+) and urea and lipid profile parameters including triglyceride, total cholesterol, high-density lipoprotein cholesterol (HDL-C), low-density lipoprotein cholesterol (LDL-C) and very low-density lipoprotein cholesterol (VLDL-C), were evaluated. All the above-mentioned parameters were evaluated using ready-to-use kits obtained from Randox Laboratory Ltd. Co. Antrim, United Kingdom based on the manufacturer's instructions.

Histological studies

The liver and kidney were fixed in 10 % formalin after the rats were sacrificed, thereafter, samples were cleaved, processed and embedded in paraffin wax. Then, the tissues were sectioned into 5- μm thickness specimen, stained with haematoxylin and eosin and evaluated under an optical microscope by an experienced pathologist as described by Fisher et al. (2002).

Statistical analysis

The results of this study were presented as mean \pm standard deviation of three replicates using excel package. The experimental data were tested for homogeneity of variance and then subjected to one-way analysis of variance (ANOVA) and the difference between the samples mean were tested by Tukey *post-hoc* test using R-statistics software version 3.03. A $p \leq 0.05$ was considered statistically significant.

Results

In acute toxicity study, any signs of abnormalities before and after treatment with aqueous-fermented extract of *M. paradisiaca* fruit pulp (500-5000 mg/kg) were recorded. No death or signs of toxicity were observed in all the groups. However, rats fed with 2000 mg/kg extracts were calm within 2 h of administration while rats treated with 5000 mg/kg could not eat enough food (Table 1). In sub-acute toxicity test, no significant differences ($p < 0.05$) were observed in percentage of weight gain and relative organ weight of all the groups (Table 2 and Figure 1). No significant differences ($p < 0.05$) were observed in the blood profile in terms of Hb, PCV, MCH and MCV while significant differences ($p < 0.05$) were observed in WBC and platelet counts of rats fed with 200, 400, 800 mg/kg of aqueous-fermented extract of *M. paradisiaca* compared to the control group (Table 3).

Table 1. Determination of acute toxicity (LD_{50}) value of aqueous-fermented extract of *M. paradisiaca*.

Group	Dose (mg/kg)	D/T	Sign of toxicity/Behavioral changes
A	0.25 ml (H_2O)	0/12	No toxic effects
I	500	0/12	No toxic effects
II	1000	0/12	No toxic effects
III	2000	0/12	Calm, but agile after 2 h
IV	5000	0/12	Calm, agile after 2 h but could not eat enough food.

D/T = Number of rat deaths/Total number of rats used.

Table 2. The effects of aqueous-fermented *M. paradisiaca* on the body weight of Wistar rats post 14 days administration.

Parameter	Control	Group II (200 mg/kg)	Group III (400 mg/kg)	Group IV (800 mg/kg)
Weight on day 1	116.00±9.54	107.67±16.44	159.67±3.79	108.67±7.51
Weight on day 14	150.60±13.58	141.00±47.13	182.67±6.66	130.33±10.79
Weight gain (g)	34.60	33.33	23.00	21.66

Values represent mean ± SD of n=6 rats in each group.

Table 3. Effects of aqueous-fermented extract of *M. paradisiaca* on haematological parameters of Wistar rats.

Parameter	Group I (control)	Group II (200 mg/kg)	Group III (400mg/kg)	Group IV (800 mg/kg)
PCV (%)	49.40±1.70	46.90±0.95	45.17±0.51	44.80±2.67
Hb (g/dl)	13.90±1.10	12.70±1.18	13.70±0.30	14.53±0.38
RBC (×10 ¹² /L)	8.90±0.30	7.00±0.11	7.25±0.07	7.52±0.04
MCV (fl)	60.40±0.20	67.53±0.34	62.63±0.42	63.63±3.99
MCH (pg)	16.50±0.10	17.11±0.79	18.60±0.19	19.09±0.32
MCHC (g/L)	278.00±1.00	256.33±10.97	266.33±26.08	304.00±23.26
WBC (×10 ⁹ /L)	17.00±1.30	10.90±0.75*	14.70±1.15	12.53±1.01*
Lymphocyte (%)	43.00±1.00	44.00±1.00	44.00±2.00	46.33±1.53
Neutrophil (%)	50.00±1.00	49.00±1.00	46.33±2.08*	42.33±2.52**
Monocyte (%)	4.80±1.00	4.67±1.15	7.33±3.06*	7.67±0.58*
Eosinophil (%)	1.67±0.58	1.67±0.58	3.00±2.00*	3.00±1.00*
Basophil (%)	0.00±0.00	0.00±0.00	0.00±0.00	0.00±0.00
Platelet (×10 ⁹ /L)	555.00±50.23	581.67±54.85*	634.33±37.61**	722.00±41.62***

Values represent mean ± SD of n=6 rats in each group. Significant differences compared to control at p<0.05 are indicated with *, **and *** showing the level of significance.

Significant decreases (p<0.05) in urea and creatinine levels were observed in the rats fed with aqueous-fermented extract of *M. paradisiaca* at all concentrations while Cl⁻ significantly reduced only at the dose of 800 mg/kg. No significant changes were observed in the serum levels of K⁺, Na⁺ and HCO₃⁻ compared to the control group (Figure 2).

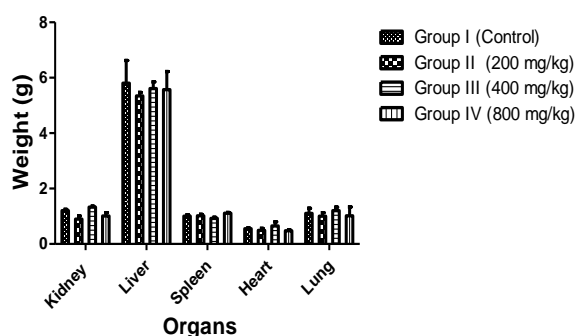


Figure 1. Effects of 14-days administration of aqueous-fermented *Musa paradisiaca* (200, 400 and 800 mg/kg body weight) on the relative organ weight of Wistar rats. Values represent mean ± SD of n=6 rats in each group. Significant differences compared to control at p<0.05 are indicated with *.

ALT showed a significant decrease in rats treated with aqueous-fermented extract of *M. paradisiaca* at all concentrations while ALP value ranged from 89.80±0.17 to 102.50±0.40 U/L and AST ranged from 9.67±2.08 to 11.00±1.00 U/L (Figure 3).

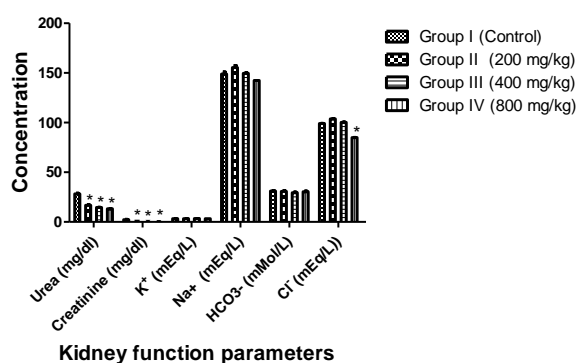


Figure 2. Effects of aqueous-fermented extract of *M. paradisiaca* on the kidney function parameters of Wistar rats. Rats were administered with aqueous-fermented extract of *M. paradisiaca* (200, 400 and 800 mg/kg body weight) for 14 days; then, rats were sacrificed and the kidney function parameters were assessed. Values represent mean ± SD of n=6 rats in each group. Significant differences compared to control at p<0.05 are indicated with *.

Toxicological Profile of *Musa paradisiaca*

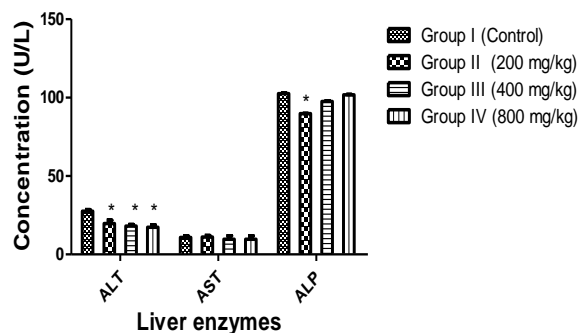


Figure 3. Effects of aqueous-fermented extract of *M. paradisiaca* on the hepatic enzymes of Wistar rats. Rats were administered with aqueous-fermented extract of *M. paradisiaca* (200, 400 and 800 mg/kg body weight) for 14 days; then, rats were sacrificed and the liver enzymes were assessed in serum. Values represent mean \pm SD of n=6 rats in each group. Significant differences compared to control at $p < 0.05$ are indicated with asterisk *.

Lipid profile investigation showed that cholesterol, LDL-C and HDL-C increased significantly ($p < 0.05$) in groups treated with 400 and 800 mg/kg extract of *M. paradisiaca* compared to the control group (Figure 4). There were no observable changes in histology of the rats' liver and kidney (Figures 5 and 6).

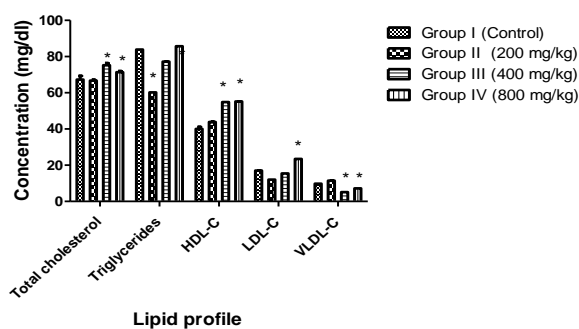


Figure 4. Effects of aqueous-fermented extract of *M. paradisiaca* on lipid profile parameters of Wistar rats. Rats were administered with aqueous-fermented extract of *M. paradisiaca* (200, 400 and 800 mg/kg body weight) for 14 days; then, animals were sacrificed and the lipid profile was determined in serum. Values represent the mean \pm SD of n=6 rats in each group. Significant differences compared to control at $p < 0.05$ are indicated with *.

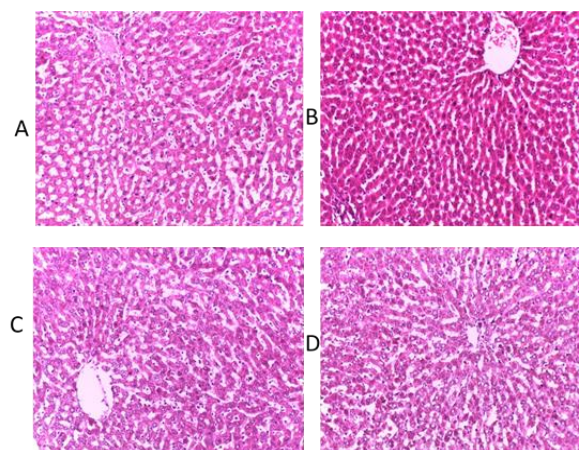


Figure 5. Micrographs of the liver sections obtained from untreated (control) rats and rats treated with various doses of aqueous-fermented extract of *M. paradisiaca* fruit pulp. Haematoxylin and eosin staining (H&E), magnification (40X). (A) control; (B) Wistar rats treated with 200 mg/kg aqueous-fermented extract of *M. paradisiaca*; (C) Wistar rats treated with 400 mg/kg aqueous-fermented extract of *M. paradisiaca*; and (D) Wistar rats treated with 800 mg/kg aqueous-fermented extract of *M. paradisiaca*.

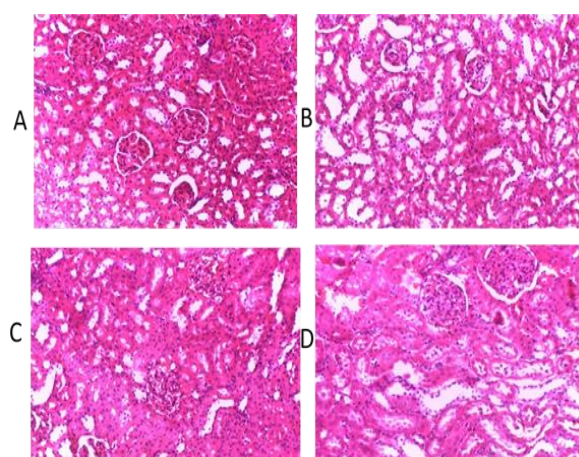


Figure 6. Micrographs of the kidney sections obtained from untreated (control) rats and rats treated with various doses of aqueous-fermented extract of *M. paradisiaca*. Haematoxylin and eosin staining (H&E), magnification (40X). (A) control; (B) Wistar rats treated with 200 mg/kg aqueous-fermented extract of *M. paradisiaca*; (C) Wistar rats treated with 400 mg/kg aqueous-fermented extract of *M. paradisiaca* and (D) Wistar rats treated with 800 mg/kg aqueous-fermented extract of *M. paradisiaca*.

Discussion

In folk medicine, various parts of *M. paradisiaca* are used in the management or treatment of many ailments such as diabetes, diarrhea, burns, hypertension, marasmus, bites, hemorrhage and ulcers. Ikpeazu *et al.* (2017) established that aqueous-fermented extract of *M. paradisiaca* has an effective anti-ulcer potential. However, regardless of various medicinal uses of *M. paradisiaca*, there is little or no comprehensive report on the toxicity profile of aqueous-fermented extract of *M. paradisiaca* fruit pulp. Aqueous-fermented extract of *M. paradisiaca* fruit pulp is used in Southeastern parts of Nigeria to treat ulcers. However, administration of this extract over a long period of time may be detrimental in the absence of proper dose monitoring or without considering its toxic effects. This study therefore investigated acute and sub-acute toxicity profile of aqueous-fermented extract of *M. paradisiaca* in rats.

Toxicity studies of substances involve acute, sub-acute, chronic, or sub-chronic toxicity (Balogun and Tom Ashafa, 2016; Kong *et al.*, 2016b). In acute toxicity studies, oral administration of fermented *M. paradisiaca* 500 and 5000 mg/kg to rats did not cause mortality nor toxicity signs. However, behavioral changes were observed at the doses of 2000 mg/kg (rats were calm within 2 h) and 5000 mg/kg (rats lost appetite for food). This is an indication that the LD₅₀ of *M. paradisiaca* extract is well above 5000 mg/kg and an LD₅₀ of >5000 mg/kg has been reported to be safe and can be considered non-toxic (OECD, 2001). Determination of organ weight in *in vivo* toxicity studies is essential for assessment of animals' sensitivity to toxicity, physiologic perturbations, induction of enzymes, and acute organ damage (Michael *et al.*, 2007). In sub-acute toxicity studies, non-significant differences ($p < 0.05$) in weight gain (Table 2) and relative organ weight (Figure 1) were

observed in all groups demonstrating normal weight increase in all groups.

Blood is regarded as an essential biological sample for assessment of physiological, nutritional and pathological status of vertebrates. Investigation of blood parameters are also useful for determination of the impact of potentially toxic substances on blood parameters (Han *et al.*, 2010). Significant increases ($p < 0.05$) which were within the internationally accepted range of the proportions of neutrophils, eosinophil and monocytes and non-significant changes in lymphocytes and basophils counts suggest that this extract did not cause any damage to the tissues nor the immune system. Significant increases in platelet counts observed in all extract-treated groups compared to control group, are possibly because of elevated secretion and production of thrombopoietin, a hormone responsible for the synthesis of platelets (Kaushansky, 1995). Hepatic and renal functions impairment caused by toxicants could be revealed by investigation of blood and biochemical parameters as liver and kidney are pivotal for survival (Olorunnisola *et al.*, 2012). ALP, AST and ALT are essential biomarkers of cellular integrity and function of the liver and heart, which are often released into the blood from damaged liver (Chavda *et al.*, 2010). Cellular damage, tissue necrosis and cardiovascular diseases lead to elevation of serum concentrations of ALT and AST (Ioannou *et al.*, 2006; Adeyemi *et al.*, 2015). In this study, serum levels of ALT significantly reduced ($p < 0.05$) while AST slightly decreased, suggesting that aqueous-fermented extract of *M. paradisiaca* may possess some hepato-protective properties.

Increases or decreases in serum electrolytes level may be caused by a hypo- or hyper-functioning organ or tissue. Kidney functions are commonly investigated by assessing the level of sodium, potassium, and chlorides in blood serum (Balogun and Tom Ashafa, 2016). The serum concentration of urea and creatinine decreased significantly ($p < 0.05$)

Toxicological Profile of *Musa paradisiaca*

while HCO_3^- , K^+ and Na^+ levels were not significantly different from those of the control group ($p < 0.05$), indicating that *M. paradisiaca* has no adverse effect on the kidney. Although, significant increases ($p < 0.05$) were observed in total cholesterol, HDL-C and LDL-C levels, the observed increases in values were within the normal range. The histological assessment of the liver and kidney showed normal architecture of the organs without any detrimental pathological changes confirming non-toxic nature of *M. paradisiaca* at tested doses (Figures 5 and 6).

In conclusion, this study revealed that the LD_{50} of aqueous-fermented extract of *M. paradisiaca* is above 5g/kg. The study also established that the oral administration of aqueous-fermented extract of *M. paradisiaca* up to the dose of 800 mg/kg for 14 days, is not toxic and therefore may be considered safe for therapeutic uses. This study also revealed that aqueous-fermented extract of *M. paradisiaca* decreased liver biomarker enzymes (e.g. ALT, AST and ALP) when compared to their respective controls, suggesting that aqueous-fermented extract of *M. paradisiaca* could have hepato-protective effects.

Acknowledgment

The authors are grateful to Abia University management team led by the Vice Chancellor Professor Uche Ikonne for providing laboratory space and equipment required for performing this experiment. This work was supported by TETFUND Institutional Base research Grant (TETFUND/ABSU/RP/2016/011).

Conflicts of interest

Authors declare no conflict of interests and are responsible for the content and data of this manuscript.

References

Adamson RH. 2016. The acute lethal dose 50 (LD_{50}) of caffeine in albino rats. Regul Toxicol Pharmacol, 80: 274-276.

- Adeolu A, Enesi D. 2013. Assessment of proximate, mineral, vitamin and phytochemical compositions of plantain (*Musa paradisiaca*) bract—an agricultural waste. Int Res J Plant Sci, 4: 192-197.
- Adeyemi OT, Osilesi O, Adebawo OO, Onajobi FD, Oyedemi SO, Afolayan A. 2015. Alkaline Phosphatase (ALP), Aspartate Aminotransferase (AST) and Alanine Aminotransferase (ALT) Activities in Selected Tissues of Rats Fed on Processed Atlantic Horse Mackerel (*Trachurus trachurus*). Adv Biosc Biotechnol, 6: 139.
- Agarwal P, Singh A, Gaurav K, Goel S, Khanna H, Goel R. 2009. Evaluation of wound healing activity of extracts of plantain banana (*Musa sapientum* var. *paradisiaca*) in rats. Indian J Exp Biol, 47: 32-40.
- Amutha K, Selvakumari U. 2016. Wound healing activity of methanolic stem extract of *Musa paradisiaca* Linn. (Banana) in Wistar albino rats. Int Wound J, 13: 763-767.
- Annor GA, Asamoah-Bonti P, Sakyi-Dawson E. 2016. Fruit physical characteristics, proximate, mineral and starch characterization of FHIA 19 and FHIA 20 plantain and FHIA 03 cooking banana hybrids. SpringerPlus, 5: 796.
- Askari VR, Baradaran Rahimi V, Ghorbani A, Rakhshandeh H. 2016. Hypnotic Effect of *Ocimum basilicum* on Pentobarbital-Induced Sleep in Mice. Iran Red Crescent Med J, 18: e24261.
- Bain BJ, Bates I, Laffan MA 2016. Dacie and Lewis practical haematology. Elsevier Health Sciences.
- Balogun FO, Tom Ashafa AO. 2016. Acute and Subchronic Oral Toxicity Evaluation of Aqueous Root Extract of *Dicoma anomala* Sond. In Wistar Rats. Evidence-Based Compl Alter Med, 2016: 11.
- Brewer HB. 1999. Hypertriglyceridemia: changes in the plasma lipoproteins associated with an increased risk of cardiovascular disease. Am J Cardiol, 83: 3-12.
- Care, Animal and Use Committee 1998. Guidelines for the capture, handling, and care of mammals as approved by the American Society of Mammalogists. J Mammal, 1416-1431.
- Chavda R, Vadalia K, Gokani RL. 2010. Hepatoprotective and antioxidant activity of root bark of *Calotropis procera* R. Br

- (Asclepiaceae). *Int J Pharmacol*, 6: 937-943.
- CNRC. 2010. Guide for the care and use of laboratory animals. National Academies Press.
- Coulibaly S, Nemlin G, Kamenan A. 2007. Chemical Composition, Nutritive and Energetic Value of Plantain (*Musa ssp.*) Hybrids CRBP 4, CRBP 39, FHIA 7, FHIA 2 and Orishele Variety. *Tropicultura*, 25: 2-6.
- Danlami U, Ijoh JJ, David BM. 2015. Phytochemical Screening, Proximate Analysis and Anti-Oxidant Activities of Ripe and Unripe Plantain Powder of *Musa paradisiaca* and *Musa accuminata*. *Am J Biosc Bioeng*, 3: 87-90.
- Dutta PK, Das AK, Banerji N. 1983. A tetracyclic triterpenoid from *Musa paradisiaca*. *Phytochem*, 22: 2563-2564.
- Eleazu CO, Okafor P. 2015. Use of unripe plantain (*Musa paradisiaca*) in the management of diabetes and hepatic dysfunction in streptozotocin induced diabetes in rats. *Interv Med Appl Sci*, 7: 9-16.
- Eleazu CO, Okafor PN, Amajor J, Awa E, Ikpeama AI, Eleazu KC. 2011. Chemical composition, antioxidant activity, functional properties and inhibitory action of unripe plantain (*M. Paradisiaceae*) flour. *Afr J Biotechnol*, 10: 16937-16947.
- Elujoba AA, Odeleye O, Ogunyemi C. 2005. Traditional medicine development for medical and dental primary health care delivery system in Africa. *Afr J Trad Comp Alt Med*, 2:46-61.
- Ezekwesili CN, Ghasi S, Adindu CS, Mefoh NC. 2014. Evaluation of the anti-ulcer property of aqueous extract of unripe *Musa paradisiaca* Linn. Peel in Wistar rats. *Afr J Pharm Pharmacol*, 8: 1006-1011.
- Fisher DI, Safrany ST, Strike P, McLennan AG, Cartwright JL. 2002. Nudix hydrolases that degrade dinucleoside and diphosphoinositol polyphosphates also have 5-phosphoribosyl 1-pyrophosphate (PRPP) pyrophosphatase activity that generates the glycolytic activator ribose 1, 5-bisphosphate. *J Biol Chem*, 277: 47313-47317.
- Han ZZ, Xu HD, Kim KH, Ahn TH, Bae JS, Lee JY, Gil KH, Lee JY, Woo SJ, Yoo HJ. 2010. Reference data of the main physiological parameters in control Sprague-Dawley rats from pre-clinical toxicity studies. *Lab Anim Res*, 26: 153-164.
- Haukioja A. 2010. Probiotics and oral health. *Eur J Dent*, 4:348-355.
- Ibukun OE, Kade IJ, Oguntoyinbo TA, Ogunmoyole T, Johnson OD. 2012. Effect of ripening on the phytochemical constituents and antioxidant properties of plantain (*Musa paradisiaca*). *J Med Plants Res*, 6: 5077-5085.
- Ikpeazu O, Elekwa I, Ugbogu A, Arunsi U, Uche-Ikonne C. 2017. Preliminary Evaluation of Anti-ulcer Potential of Aqueous Extract of Fermented Unripe *Musa paradisiaca* in Wistar Rats. *Am J Biomed Res*, 5: 17-23.
- Imam MZ, Akter S. 2011. *Musa paradisiaca* L. and *musa sapientum* L.: A phytochemical and pharmacological review. *J Appl Pharm Sci*, 01:14-20.
- Ioannou GN, Weiss NS, Boyko EJ, Mozaffarian D, Lee SP. 2006. Elevated serum alanine aminotransferase activity and calculated risk of coronary heart disease in the United States. *Hepatology*, 43: 1145-1151.
- Jawla S, Kumar Y, Khan M. 2012. Antimicrobial and antihyperglycemic activities of *Musa paradisiaca* flowers. *Asian Pac J Trop Biomed*, 2: S914-S918.
- Kapadia SP, Pudukalkatti PS, Shivanaikar S. 2015. Detection of antimicrobial activity of banana peel (*Musa paradisiaca* L.) on *Porphyromonas gingivalis* and *Aggregatibacter actinomycetemcomitans*: An in vitro study. *Contemp Clin Dent*, 6: 496-499.
- Kaushansky K. 1995. Thrombopoietin: the primary regulator of megakaryocyte and platelet production. *Thromb and Haemos*, 74: 521-525.
- Ketiku AO. 1973. Chemical composition of unripe (green) and ripe plantain (*musa paradisiaca*). *J Sci Food Agric*, 24: 703-707.
- Kiin-Kabari DB, Giami SY. 2015. Physico-Chemical, Starch Fractions and Dietary Fibre of Biscuits Produced from Different Levels of Substitution of Wheat Flour with Plantain Flour. *Int J Food Sci Nutri Engn*, 5: 197-202.
- Kong BH, Tan NH, Fung SY, Pailoor J. 2016a. Sub-Acute Toxicity Study of Tiger Milk Mushroom *Lignosus tigris* Chon S. Tan Cultivar E *Sclerotium* in Sprague Dawley Rats. *Front Pharmacol*, 7:246.

Toxicological Profile of *Musa paradisiaca*

- Kong BH, Tan NH, Fung SY, Pailoor J, Tan CS, Ng ST. 2016b. Nutritional composition, antioxidant properties, and toxicology evaluation of the sclerotium of Tiger Milk Mushroom *Lignosus tigris* cultivar E. *Nutri Res*, 36: 174-183.
- Liong MT, Fung WY, Ewe JA, Kuan CY, Lye HS. 2009. The improvement of hypertension by probiotics: effects on cholesterol, diabetes, renin, and phytoestrogens. *Int J Mol Sci*, 10:3755–75.
- Michael B, Yano B, Sellers RS, Perry R, Morton D, Roome N, Johnson JK, Schafer K. 2007. Evaluation of organ weights for rodent and non-rodent toxicity studies: a review of regulatory guidelines and a survey of current practices. *Toxicol Pathol*, 35: 742-750.
- Neuwinger HD. 2000. African traditional medicine: a dictionary of plant use and applications. With supplement: search system for diseases. Medpharm.
- Nirmala M, Girija K, Lakshman K, Divya T. 2012. Hepatoprotective activity of *Musa paradisiaca* on experimental animal models. *Asian Pac J Trop Biomed*, 2: 11-15.
- Musa H, Wu S, Zhu C, Seri H, Zhu G. 2009. The potential benefits of probiotics in animal production and health. *J Anim Vet Adv*, 8:313-321.
- OECD. 2001. Organization for economic cooperation and development Guideline 423. Acute oral toxicity- acute toxic class method. 470 adopted by the council on 17th, December 2001.
- OECD. 1995. Organization for economic cooperation and development Guideline 407. Repeated-dose 28-day oral toxicity study in rodents. 468 adopted by the council on 27th, July 1995.
- Ojewole J, Adewunmi C. 2003. Hypoglycemic effect of methanolic extract of *Musa paradisiaca* (Musaceae) green fruits in normal and diabetic mice. *Exp Clin Pharmacol*, 25: 453-456.
- Olorunnisola O, Bradley G, Afolayan A. 2012. Acute and sub-chronic toxicity studies of methanolic extract of *Tulbaghia violacea* rhizomes in Wistar rats. *Afr J Biotechnol*, 11: 14934-14940.
- Rao U, Suryati MK, Abdurrazaq M, Ahmad BA, Mohaslinda M, Ali RM. 2014. Taxonomical, Phytochemical and Pharmacological Reviews of *Musa sapientum* var. *Paradisiaca*. *Res J Pharm Technol*, 7: 1356-1361.
- Shodehinde SA, Oboh G. 2013. Antioxidant properties of aqueous extracts of unripe *Musa paradisiaca* on sodium nitroprusside induced lipid peroxidation in rat pancreas in vitro. *Asian Pac J Trop Biomed*, 3: 449-457.
- Ugbogu EA, Okezie E, Elekwa I, Uhegbu F, Akubugwo E, Chinyere CG, Ewuzie F, Ugorji CJ. 2016. Toxicological assessment of the aqueous dried leaf extracts of *Senna alata* L. in wistar rats. *Afr J Pharm Pharmacol*, 10: 709-717.
- World Health Organization. 2002. WHO Trad Med Strat, 2002-2005.
- Yakubu MT, Nurudeen QO, Salimon SS, Yakubu MO, Jimoh RO, Nafiu MO, Akanji MA, Oladiji AT, Williams FE. 2015. Antidiarrhoeal Activity of *Musa paradisiaca* Sap in Wistar Rats. *Evidence-Based Compl Alter Med*, 2015: 9.
- Zhang X. 2000. General guidelines for methodologies on research and evaluation of traditional medicine. WHO, 1-71.