

Original Research Article

Evaluation of acute and sub-acute toxicity of *Pinus eldarica* bark extract in Wistar rats

Akram Ghadirkhomi¹, Leila Safaeian^{2*}, Behzad Zolfaghari³, Mohammad Reza Agha Ghazvini⁴, Parisa Rezaei⁵

¹Department of Pharmacology, Islamic Azad University, Shahreza Branch, Shahreza, Iran

²Department of Pharmacology and Toxicology, Isfahan Pharmaceutical Sciences Research Center, School of Pharmacy and Pharmaceutical Sciences, Isfahan University of Medical Sciences, Isfahan, Iran

³Department of Pharmacognosy, School of Pharmacy and Pharmaceutical Sciences, Isfahan University of Medical Sciences, Isfahan, Iran

⁴Isfahan Center of Public Health Training and Research, Institute of Public Health Research, Tehran University of Medical Science, Iran

⁵Department of Pathology, Seyed-Al-Shohada Hospital, Isfahan, Iran

Article history:

Received: Oct 10, 2015

Received in revised form:

Nov 18, 2015

Accepted: Dec 08, 2015

Vol. 6, No. 5, Sep-Oct 2016,

558-566.

*** Corresponding Author:**

Tel: +983137927087

Fax: +983136680011

leila_safaeian@pharm.mui.ac.ir

Keywords:

Pinus eldarica

Toxicity

Hematology

Serum biochemistry

Histopathology

Abstract

Objective: *Pinus eldarica* (*P. eldarica*) is one of the most common pines in Iran which has various bioactive constituents and different uses in traditional medicine. Since there is no documented evidence for *P. eldarica* safety, the acute and sub-acute oral toxicities of hydroalcoholic extract of *P. eldarica* bark were investigated in male and female Wistar rats in this study.

Materials and Methods: In the acute study, a single dose of extract (2000 mg/kg) was orally administered and animals were monitored for 7 days. In the sub-acute study, repeated doses (125, 250 and 500 mg/kg/day) of the extract were administered for 28 days and biochemical, hematological and histopathological parameters were evaluated.

Results: Our results showed no sign of toxicity and no mortality after single or repeated administration of *P. eldarica*. The median lethal dose (LD₅₀) of *P. eldarica* was determined to be higher than 2000 mg/kg. The mean body weight and most of the biochemical and hematological parameters showed normal levels. There were only significant decreases in serum triglyceride levels at the doses of 250 and 500 mg/kg of the extract in male rats ($p < 0.05$ and $p < 0.01$, respectively) and in monocyte counts at the highest dose of the extract in both male and female rats ($p < 0.05$). Mild inflammation was also found in histological examination of kidney and liver tissues at the highest dose of extract.

Conclusion: Oral administration of the hydroalcoholic extract of *P. eldarica* bark may be considered as relatively non-toxic particularly at the doses of 125 and 250 mg/kg.

Please cite this paper as:

Ghadirkhomi A, Safaeian L, Zolfaghari B, Aghaye-Ghazvini MR, Rezaei P. Evaluation of acute and sub-acute toxicity of *Pinus eldarica* bark extract in Wistar rats. Avicenna J Phytomed, 2016; 6 (5): 558-566.

Introduction

Herbal medicines are getting considerable interest worldwide. According to the report of the World Health Organization (WHO), herbal medicines are presently used for prevention and treatment of diseases by 80% of people in developing countries. In developed countries, the public interest in herbal prescriptions has also greatly increased (Aschwanden, 2001). Despite the wide use of medicinal plants, their safety and efficacy have not been fully investigated and more detailed analysis is therefore warranted for evaluation and standardization of herbal formulations (WHO, 2008).

Pinaceae or pine family is comprised of several popular conifers with diverse species in 11 genera. *Pinus* as the largest genus in pinaceae family contained numerous long-lived and evergreen trees which broadly spread in many countries including Iran (Farjon, 2005).

Pinus eldarica Medw. (*P. eldarica*) is one of the most common pines in Iran. In traditional medicine, different parts of *P. eldarica* (needles, buds, resin and nuts) are used for the treatment of some diseases including asthma, allergic rashes, dermatitis and wounds (Mamedov and Craker, 2001; Mamedov et al., 2005). In pharmacological studies, the blood glucose lowering effect and hypotriglyceridemic and anti-urolithiatic activities have been shown for *P. eldarica* extract (Fallahhuseini et al., 2013; Huseini et al., 2015; Hosseinzadeh et al., 2010). The presence of various biologically active components such as α -pinene, β -pinene, β -caryophyllene, longifolene, α -humulene, δ -3-carene and junipene and high quantities of phenolic compounds including catechin, ferulic acid, caffeic acid, and taxifolin have been recognized in phytochemical analysis of leaves, fruits and bark extracts of *P. eldarica* (Afsharypour and Sanaty, 2005; Zolfaghari and Iravani, 2012).

Since there is no documented evidence for *P. eldarica* safety, the present study

aimed to investigate the acute and sub-acute toxicity profile of the hydroalcoholic extract of *P. eldarica* bark in rats.

Materials and Methods

Plant material and preparation of extract

P. eldarica barks were collected from Isfahan city (center of Iran) in Isfahan Province in August 2014. Following identification of the plant by a botanist, a voucher specimen (No. 3318) was deposited at the Herbarium of the School of Pharmacy and Pharmaceutical Sciences, Isfahan, Iran. For preparation of hydroalcoholic extract, the barks of *P. eldarica* were powdered to coarse particles and macerated with ethanol (70%) at room temperature for 72 hr and the process was repeated for three times. After filtration (using Whatman filter paper No. 1 (11 μ m pore size)), the solvent was removed using a rotary evaporator under low pressure. The obtained viscous residue was freeze-dried and stored at -20 °C. The yield of the plant extraction was 20 % (w/w).

Determination of total phenolic content

The total phenolic content of the hydroalcoholic extract of *P. eldarica* was assessed using Folin-Ciocalteu method which is also called the gallic acid equivalence method. This assay is used for characterization of the plant extract and standardization and normalization of the polyphenols content in the extracts.

In this method, Folin-Ciocalteu reagent which is a mixture of phosphomolybdate and phosphotungstate was used for the colorimetric evaluation of phenolic and polyphenolic antioxidants only in *in vitro* experiments (Singleton et al., 1999).

Briefly, the plant samples were mixed with sodium bicarbonate (20%). The mixture was then treated with diluted Folin-Ciocalteu reagent. After 2 hr, the absorbance was measured using a spectrophotometer (Bio-Tek, PowerWave XS, USA) at 765 nm. The total phenol

content was estimated using a standard curve obtained from various concentrations of gallic acid (50, 100, 150, 250 and 500 mg/l) and expressed in terms of gallic acid as the standard (Yoo *et al.*, 2008).

Experimental animals

Wistar rats of both sexes (200 ± 20 g, 6 weeks old) were obtained from the animal house of the School of Pharmacy and Pharmaceutical Sciences, Isfahan, Iran and used in acute and sub-acute toxicity studies. The animals were maintained under standard laboratory conditions with 12 hr/ 12 hr light/dark cycles at around 22 °C in polypropylene cages with free access to tap water and standard pellet diet. The experiments were performed according to the international guidelines for laboratory animal use and care.

Acute oral toxicity study

For acute toxicity study, the single test dose of 2000 mg/kg of the hydroalcoholic extract of *P. eldarica* in normal saline was administered to the female and male rats orally using an intra-gastric tube. The rats were fasted overnight prior to extract administration. The control groups received equal volume of normal saline orally. Five animals were used in each control and experimental groups. All rats were observed at 1, 2 and 4 hr after treatment and periodically during the first 24 hr then, daily until 7 days for mortality or any delayed sign of toxicity. Any changes in skin, hair, eyes and mucus membrane, food and water consumption, bodyweight, respiratory rate and behavioral, neurological and autonomic profiles were noted during the test period (OECD, 2002). Animals were sacrificed under ether anesthesia at the end of the experiment.

Sub-chronic oral toxicity study

In sub-acute toxicity study, forty female and male rats (five in each group) received daily oral administration (OECD, 2002) of the hydroalcoholic extract of *P. eldarica*

(125, 250 and 500 mg/kg) or equal volume of normal saline for 28 days (Farah-Amna *et al.*, 2013). All rats were weighed prior to dosing and every four days during the test period. At the end of the experiment, 12 hr-fasting rats were anesthetized with ether. The blood samples were taken from the heart by direct puncture and collected in tubes containing heparin or EDTA for biochemical and hematological analysis, respectively. The liver and kidneys were removed for histopathological examination.

Biochemical analysis

The effects of *P. eldarica* extract on the biochemical parameters were assessed by estimation of the following parameters including plasma alanine aminotransferase (ALT), aspartate aminotransferase (AST), alkaline phosphatase (ALP), total protein, glucose, urea, uric acid, creatinine, total cholesterol, triglyceride, high density lipoprotein (HDL) and low density lipoprotein (LDL) cholesterol. The parameters were measured by an enzymatic colorimetric method using commercially available kits by a spectrophotometer (Hitachi 902 auto analyzer, Japan).

Hematological analysis

The effects of *P. eldarica* extract on the hematological parameters including white blood cells (WBC) and differential leukocyte (neutrophil, lymphocyte, eosinophil and basophil), red blood cells (RBC), hematocrit (Hct), haemoglobin (Hb), platelets count, and mean corpuscular volume (MCV), mean corpuscular hemoglobin (MCH), mean corpuscular hemoglobin concentration (MCHC), mean platelet volume (MPV), and red distribution width (RDW) were estimated using automated hematology analyzer.

Histopathological examination

After sacrificing the rats, liver and kidney tissues were collected for the histological studies. The tissues were fixed in 10% buffered formalin, embedded in

Acute and sub-acute toxicity of *P. eldarica*

paraffin, sectioned at approximately 4 μm thickness and stained with hematoxylin and eosin (H&E) for examination by light microscopy. The histological changes in liver and kidney tissues were scored in a blinded fashion as follows: grade 0=normal tissue showing no changes; grade 1= very mild inflammatory changes; grade 2=mild, grade 3=moderate and grade 4=severe inflammatory changes (Arsad et al., 2014)

Statistical analysis

Values were reported as mean \pm standard error of mean (SEM). Data analysis was made by one-way analysis of variance (ANOVA) followed by Tukey post-hoc test using SPSS software version 16.0. Pathological scores were analyzed by the nonparametric Kruskal-Wallis test. $P < 0.05$ was considered to be statistically significant.

Results

Total phenolic content of *P. eldarica*

The total phenolic content was estimated as 38.1 ± 1.5 % gallic acid equivalents in the extract of *P. eldarica* bark.

Acute oral toxicity study of *P. eldarica*

Rats receiving the fixed dose of hydroalcoholic extract of *P. eldarica* bark (2000 mg/kg) did not show any clinical signs of toxicity during the observational period of 7 days. There were no abnormal gross findings in the males and female rats. No significant changes in the body weight gains were detected. All animals survived and no mortality was observed until the end of the experiment indicating that the median lethal dose (LD_{50}) of *P. eldarica* extract is higher than 2000 mg/kg for both male and female rats.

Sub-acute toxicity of *P. eldarica*

Here, 28-day administration of *P. eldarica* hydroalcoholic extract (125, 250 and 500 mg/kg) did not cause any mortality in female and male rats. There

was no sign of toxicity during the experimental period as compared to the control groups. There was a progressive increase in body weights of control and *P. eldarica* extract-treated rats and no significant difference in the mean body weight was observed between the control and tested animals (Figures 1A and 1B).

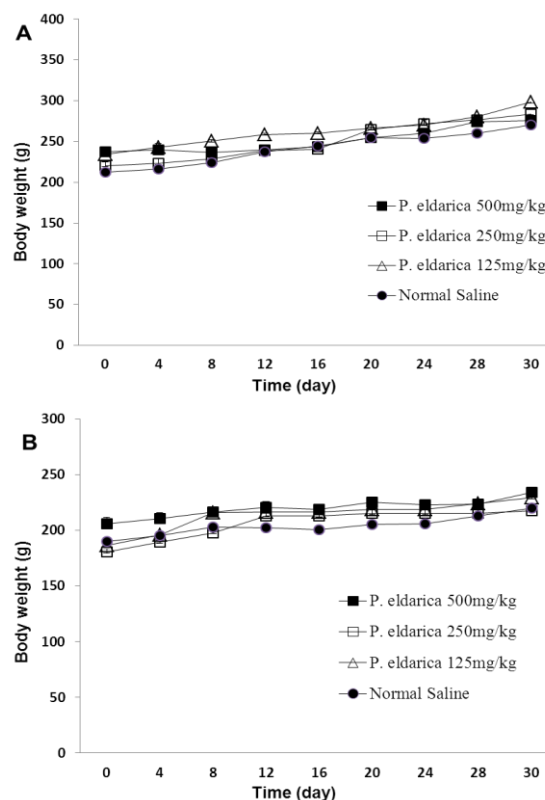


Figure 1. The effect of hydroalcoholic extract of *P. eldarica* (125, 250 and 500 mg/kg) on mean body weight in male (A) and female (B) rats in sub-acute toxicity study. Values are means + SEM for five rats.

In biochemical analysis, a statistically significant decrease in serum triglyceride level was observed at the doses of 250 and 500 mg/kg of *P. eldarica* extract in male rats compared to the control group ($p < 0.05$ and $p < 0.01$, respectively). The effect of sub-acute administration of *P. eldarica* extract on biochemical parameters is presented in Table 1. All other parameters including various lipid markers, blood sugar, total protein, hepatic biomarker enzymes (ALT, AST and ALP), and renal biochemical parameters (urea, uric acid and creatinine) showed normal levels.

Table 1. Effect of sub-acute administration of *P. eldarica* extract on biochemical parameters in female and male rats (n = 5).

	Male				Female			
	Control	125	250	500	Control	125	250	500
Blood sugar (mg/dl)	157.2 ± 11.29	160 ± 21.28	147.6 ± 0.93	172.6 ± 25.8	198.6 ± 26.10	198.3 ± 23.70	190.4 ± 0.80	191 ± 15.04
Urea (mg/dl)	31.6 ± 4.96	32.8 ± 4.14	33.2 ± 6.47	31.2 ± 3.43	48.8 ± 5.21	44.4 ± 3.37	49.4 ± 4.78	47.5 ± 4.57
Creatinine (mg/dl)	0.74 ± 0.07	0.54 ± 0.07	0.56 ± 0.04	0.54 ± 0.02	0.48 ± 0.04	0.54 ± 0.06	0.72 ± 0.1	0.60 ± 0.05
Uric acid (mg/dl)	0.94 ± 0.05	1.72 ± 0.51	1.36 ± 0.32	1.06 ± 0.22	1.14 ± 0.12	1.28 ± 0.16	1.90 ± 0.36	0.98 ± 0.23
Cholesterol (mg/dl)	90 ± 3.13	97.2 ± 4.48	97 ± 3.24	87.4 ± 1.96	92.8 ± 1.02	98.2 ± 6.5	97.8 ± 6.27	98.1 ± 1.28
Triglycerides (mg/dl)	179.2 ± 19.12	156.6 ± 8.69	120* ± 16.27	103.4** ± 24.7	160.4 ± 18.1	151.6 ± 21.06	159.6 ± 24.2	170.2 ± 21.27
HDL (mg/dl)	38 ± 1.23	41.4 ± 2.32	43.6 ± 3.17	40.4 ± 1.63	44 ± 1.55	37.8 ± 2.35	46.6 ± 4.85	56.4 ± 1.96
LDL (mg/dl)	16.6 ± 3	18.52 ± 1.62	16.78 ± 3.29	16.3 ± 3.29	16.7 ± 3.99	18.1 ± 3.01	16.7 ± 4.45	17.76 ± 3.98
AST (IU/L)	77.8 ± 11.33	77.6 ± 24.07	79.4 ± 19.82	71.9 ± 18.81	63.2 ± 21.4	51.6 ± 12.02	52.4 ± 12.1	55.6 ± 9.3
ALT (IU/L)	59.8 ± 7.79	63.2 ± 9.5	61.8 ± 9.3	62.8 ± 9.78	56.1 ± 16.61	48.2 ± 7.54	49.8 ± 19.15	48.6 ± 17.95
ALP (IU/L)	478 ± 44.38	455 ± 55.97	337 ± 54.9	325 ± 39.05	278 ± 56.83	296 ± 69.78	255 ± 44.2	320 ± 62.11
Protein (g/dL)	5.22 ± 0.29	5.68 ± 0.27	5.94 ± 0.23	5.92 ± 0.35	6.0 ± 0.16	5.90 ± 0.17	6.42 ± 0.16	6.44 ± 0.23

* p < 0.05 and ** p < 0.01 show significant differences as compared to the corresponding control.

Table 2. Effect of sub-acute administration of *P. eldarica* extract on hematological parameters in female and male rats (n = 5).

	Male				Female			
	Control	125	250	500	Control	125	250	500
WBC (10 ³ /μl)	7.52 ± 0.54	7.49 ± 0.56	7.18 ± 1.03	7.23 ± 0.23	5.60 ± 7.10	6.71 ± 0.56	6.70 ± 0.49	5.52 ± 0.81
Neutrophils (%)	12.8 ± 4.88	14 ± 8.3	15.2 ± 6.85	10.4 ± 3.35	9.6 ± 3.76	9.4 ± 4.72	10.2 ± 7.3	9.2 ± 6.25
Lymphocyte (%)	85.4 ± 5.89	76.2 ± 8.26	82.8 ± 7.62	88.4 ± 3.49	88.6 ± 4.61	82.6 ± 5.19	77.4 ± 7.92	76.8 ± 7.18
Eosinophil (%)	0.4 ± 0.25	0.5 ± 0.55	0.8 ± 0.38	0.8 ± 0.36	1 ± 0.55	1.3 ± 0.25	1 ± 0.32	1.2 ± 0.38
Monocyte (%)	1.4 ± 0.78	1.8 ± 0.49	1.2 ± 0.58	0.25* ± 0.6	1.4 ± 0.68	1.6 ± 0.6	2 ± 0.89	0.8* ± 0.86
RBC (10 ³ /μl)	7.65 ± 0.12	7.6 ± 0.21	7.8 ± 0.55	7.35 ± 0.21	6.8 ± 0.19	7 ± 0.09	6.7 ± 0.18	7 ± 0.2
Hb (g/dL)	13.54 ± 0.21	12.85 ± 0.65	14.12 ± 0.83	13.3 ± 0.39	11.96 ± 0.64	12.72 ± 0.18	12.52 ± 0.35	12.98 ± 0.24
HCT (%)	38.16 ± 0.69	37 ± 1.77	39.92 ± 2.85	37.35 ± 1.09	34.24 ± 0.88	35.65 ± 0.66	35.57 ± 1.19	35.66 ± 0.89
MCV (fL)	49.84 ± 0.42	48.17 ± 1.93	50.9 ± 0.3	50.9 ± 0.99	50.1 ± 2.26	50.8 ± 0.74	52.4 ± 0.84	50.56 ± 0.58
MCH (pg)	17.68 ± 0.6	16.72 ± 0.8	18 ± 0.38	18.15 ± 0.34	17.56 ± 1.28	18.19 ± 0.13	18.47 ± 0.28	18.52 ± 0.34
MCHC (g/dL)	34.8 ± 6.93	37 ± 6.57	35.18 ± 0.59	35.4 ± 9.88	34.8 ± 1.17	38.7 ± 9.87	36.4 ± 1.44	36.4 ± 1.2
Platelets (10 ³ /μl)	655 ± 44.43	743 ± 60.09	746 ± 37.42	693 ± 54.5	641 ± 75.84	694 ± 12.68	751 ± 49.05	760 ± 73.22
RDW (%)	15 ± 0.16	16.3 ± 1.51	15.8 ± 0.35	15 ± 0.32	16.3 ± 1.51	14.5 ± 0.22	14.2 ± 0.35	15.9 ± 0.42

* p < 0.05 shows significant differences as compared to the corresponding control.

Acute and sub-acute toxicity of *P. eldarica*

Table 2 shows the effects of *P. eldarica* extract on the hematological parameters in sub-acute study. Monocytes were significantly decreased at the dose of 500 mg/kg of *P. eldarica* extract in both male and female rats ($p < 0.05$). All other hematological parameters showed no significant changes and remained within physiological range after the 28-day experimental period. Histopathological examination of kidney tissues following sub-acute administration of *P. eldarica* revealed mild inflammation including acute or chronic infiltration of inflammatory cells especially around large vascular structure and pyelocaliceal system at the dose of 500 mg/kg (Figure 2B). Histological analysis of liver tissues also showed very mild to mild inflammation and slight infiltration of lymphocytes after treatment of rats with 500 mg/kg of *P. eldarica* extract in sub-acute toxicity study (Figure 3B). Figure 4 represents the semiquantitative scoring of histopathological changes in kidney and liver tissues after sub-acute administration of *P. eldarica* extract.

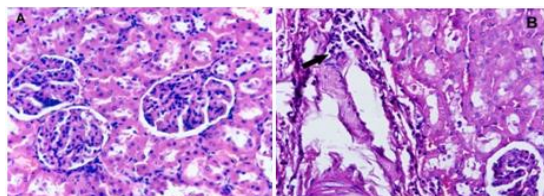


Figure 2. Hematoxylin and eosin stained sections of kidney tissues of control (A) and rats treated with *P. eldarica* extract (500 mg/kg; B) in sub-acute toxicity study (magnification, x400). Mild inflammation with perivascular chronic infiltration is seen in rats treated with high dose of *P. eldarica* for 28 days (Arrow in B).

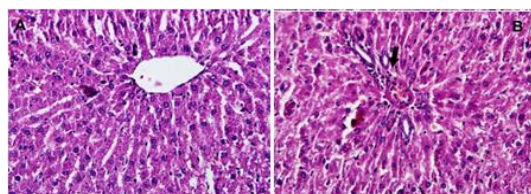


Figure 3. Hematoxylin and eosin stained sections of liver tissues of control (A) and rats treated with *P. eldarica* extract (500 mg/kg; B) in sub-acute toxicity study (magnification, x400). Very mild inflammation with perivascular infiltration is seen in rats treated with high dose of *P. eldarica* for 28 days (Arrow in B).

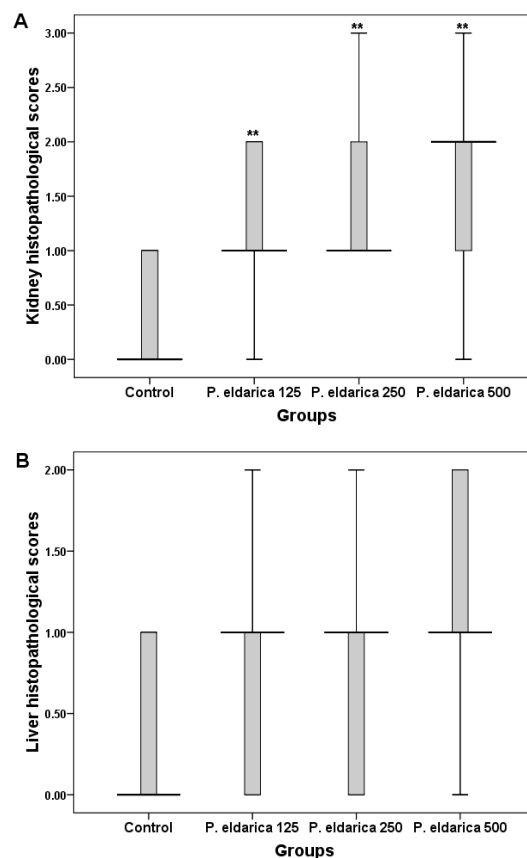


Figure 4. Semiquantitative scoring of kidney (A) and liver (B) histopathologic changes after sub-acute administration of *P. eldarica* extract (125, 250 and 500 mg/kg). Control mice received equal volume of normal saline. Thick lines represent the median of $n = 10$ (male and female rats), boxes show the interquartile range and bars represent the maximum and minimum sample values. ** $p < 0.01$ (Asymptotic significance level) as compared to control.

Discussion

Although herbal medicine as the most common form of alternative medicine are widely used for treatment of various diseases all over the world, their toxicities and side effects are poorly known (Neergheen-Bhujun, 2013). The presence of many bioactive compounds with mechanisms of action similar to conventional synthetic drugs could predict the potential toxic and adverse effects of phytomedicines (Ogbonnia et al., 2009). Toxicological cases of aristolochic acids and pyrrolizidine alkaloids and herbal-related nephrotoxicity and hepatotoxicity are well known toxicities of herbal medicine and phytochemicals (Chan et al., 2007; McLean, 1970). Allergic responses

or anaphylaxis, cardiac toxicity and even carcinogenicity are other examples of dangerous adverse effects following the use of some herbal remedies (Mullins, 1998; But et al., 1994; Nortier et al., 2000). The herbal toxic effects may be related to the intrinsic toxicity or may be due to overdosing, prolonged usage, herb-herb or herb-drug interaction and contaminated formulations (Ko, 1999). Therefore, precise evaluation of herbal medicines for toxicity and screening of bioactive components should be considered for establishing their safety and efficacy (Ogbonnia et al., 2008).

This study evaluated the toxicity of oral administration of the hydroalcoholic extract of *P. eldarica* bark in rats. Both sexes of the animals were allocated in each group because toxicological studies have shown small differences in sensitivity between females and males (OECD, 2000).

According to the fixed dose method as described in OECD guideline, single doses of 5, 50, 300 and 2000 mg/kg in a stepwise procedure could be used for acute toxicity study. The dose expected to produce some signs of toxicity without producing severe toxic effects or mortality could be selected as a starting dose level (OECD, 2002). In this study, the limit dose of 2000 mg/kg was used for acute toxicity evaluation because no sign of toxicity has been reported following administration of 500 mg/kg of *P. eldarica* extract in previous pharmacological studies (Bolandghamat et al., 2011). Our results showed no abnormal gross alteration and no mortality up to the dose of 2000 mg/kg of *P. eldarica*. Single oral administration of substances in the range of 2000-5000 mg/kg bodyweight in rodents is the most common form of acute systemic toxicity testing for defining the range of lethal dose and the effects on important physiologic functions. However, when a limit dose of at least 2000 mg/kg is used and no lethality is recognized, no further testing will be necessary for acute oral toxicity. Due to animal welfare concern, toxicity analysis with dose of

5000 mg/kg is discouraged and should only be used when there is a significant probability for a direct relevance between the results of this test with human health (OECD, 2002). According to the international standards for classification of hazards, following acute exposure, *P. eldarica* extract could be regarded as relatively low toxic agent since its oral LD₅₀ is estimated to be higher than 2000 mg/kg (GHS, 2011).

In sub-acute toxicity study, the effect of repeated oral doses of *P. eldarica* extract for a period of 28 days was evaluated. The long-term toxicity testing could provide data about persistent or cumulative toxic effects on target organ systems, dose-response relationship and also about the no-observed-adverse-effect level (NOAEL) (OECD, 2008). Our results showed no sign of toxicity and no mortality after repeated administration of *P. eldarica*.

Most of biochemical parameters including hepatic and renal biomarkers showed normal levels proposing no significant adverse effect for *P. eldarica* extract on hepato-renal functions. However, there were some histopathological changes in kidney and liver tissues of the high-dose groups as mild inflammation. These changes may be attributed to the biotransformation and elimination of active constituents of this plant. More studies are required to obtain the pharmacokinetic data of *P. eldarica* extract. Administration of the extract also caused a significant decrease in serum triglyceride levels at the higher doses in male rats suggesting its potential as a possible therapeutic agent in hypertriglyceridemia. Although Fallahhuseini and his coworkers have reported the inability of *P. eldarica* nut extract to change the fasting blood cholesterol and triglyceride levels in hypercholesterolemic diabetic rats (Fallahhuseini et al., 2013), Huseini et al. have recently shown the efficacy of *P. eldarica* nut on lowering blood cholesterol

level in hypercholesterolemic rabbits (Huseini et al., 2015).

There are also evidence for beneficial cardio-vascular and cholesterol lowering effects of other species and other parts of the pine such as *P. pinaster* bark extract (Gulati, 2005). It has been also reported that the ethyl acetate extract of *P. morrisonicola* needle extract has anti-atherosclerotic activity and protective effects against LDL oxidation (Yen et al., 2008). Interestingly, the hypotriglyceridemic effect of *P. eldarica* extract was found only in male rats in our results. Some evidence has shown sex difference in triglyceride/fatty acid substrate cycling of adipose tissue in rats which is indirectly controlled by androgens (Hansson et al., 1991).

In hematological analysis, *P. eldarica* extract similarly had no adverse effect on most of hematological parameters in sub-acute study. There was only significant decrease in monocyte counts at the highest dose of extract indicating some mild effect on the blood parameters.

In conclusion, the toxicity data obtained during this study revealed that the hydroalcoholic extract of *P. eldarica* bark is relatively non-toxic followin oral administration especially at the doses of 125 and 250 mg/kg. Regarding the presence of various phytochemical and polyphenolic compounds in different part of *P. eldarica* and several uses in traditional medicine, further detailed investigations are needed to explore the precise safety profile of this plant.

Acknowledgments

The content of this paper is extracted from the MSc thesis in medical toxicology submitted by A. Ghadrkhomi.

Conflict of interest

The authors declare no conflicts of interest.

References

- Afsharypour S, Sanaty F. 2005. Essential oil constituents of leaves and fruits of *Pinus eldarica* Medw. *J Essential oil Res*, 17: 327-328.
- Aschwanden C. 2001. Herbs for health, but how safe are they? *Bull World Health Organ*, 79: 691-692.
- Arsad SS, Esa NM, Hamzah H. 2014. Histopathologic changes in liver and kidney tissues from male Sprague Dawley rats treated with *Rhaphidophora decursiva* (Roxb.) schott extract. *J Cytol Histol*, S4: 1-6.
- Bolandghamat S, Moghimi A, Iranshahi M. 2011. Effects of ethanolic extract of pine needles (*Pinus eldarica* Medw.) on reserpine-induced depression-like behavior in male Wistar rats. *Pharmacogn Mag*, 7: 248-253.
- But PPH, Tai YT, Young K. 1994. Three fatal cases of herbal aconite poisoning. *Vet Hum Toxicol*, 36: 212-215.
- Chan W, Lee KC, Liu N, Cai ZW. 2007. A sensitivity enhanced high-performance liquid chromatography fluorescence method for the detection of nephrotoxic and carcinogenic aristolochic acid in herbal medicines. *J Chromatogr A*, 1164: 113.
- Fallahhuseini H, Mehrzadi S, Ghaznavi H, Tajallizadehkhoob Y, Fakhrzadeh H. 2013. Effects of *Pinus eldarica* Medw. nut extract on blood glucose and cholesterol levels in hypercholesterolemicalloxan-induced diabetic rats. *J Med Plants*, 12: 68-74.
- Farah-Amna O, Nooraain H, Noriham A, Azizah AH, Nurul-Husna R. 2013. Acute and oral subacute toxicity study of ethanolic extract of *Cosmos caudatus* leaf in Sprague Dawley rats. *Int J Biosci Biochem Bioinforma*, 3: 301-305.
- Farjon A. 2005. *Pines: drawings and description of the genus Pinus*, 2nd revised edition, pp. 235, Leiden, Brill Academic Publishers.
- Gulati OP. 2005. The nutraceutical Pycnogenol: its role in cardiovascular health and blood glucose control. *Biom Rev*, 16: 49-57.
- Hansson P, Saggerson D, Nilsson-Ehle P. 1991. Sex difference in triglyceride/fatty acid substrate cycling of rat adipose tissue:

- indirect regulation by androgens. *Horm Metab Res*, 23: 465-468.
- Hosseinzadeh H, Khooei A, Khashayarmanesh Z, Motamed-Shariaty V. 2010. Antiurolithiatic activity of *Pinus eldarica* Medw. fruits aqueous extract in rats. *Urol J*, 7: 232-237.
- Huseini HF, Anvari MS, Khoob YT, Rabbani S, Sharifi F, Arzaghi SM, Fakhrzadeh H. 2015. Anti-hyperlipidemic and anti-atherosclerotic effects of *Pinus eldarica* Medw. nut in hypercholesterolemic rabbits. *Daru*, 23:32.
- Ko R. 1999. Adverse reactions to watch for in patients using herbal remedies. *West J Med*, 171: 181-186.
- Mamedov N, Craker LE. 2001. Medicinal plants used for the treatment of bronchial asthma in Russia and Central Asia. *J Herbs Spices Med Plants*, 8: 91-117.
- Mamedov N, Gardner Z, Craker LE. 2005. Medicinal plants used in Russia and Central Asia for the treatment of selected skin conditions. *J Herbs Spices Med Plants*, 11: 191- 222.
- McLean EK. 1970. The toxic actions of pyrrolizidine (Senecio) alkaloids. *Pharmacol Rev*, 22: 429-482.
- Mullins RJ. 1998. Echinacea-associated anaphylaxis. *Med J Aust*, 168: 170-171.
- Neergheen-Bhujun VS. 2013. Underestimating the toxicological challenges associated with the use of herbal medicinal products in developing countries. *Biomed Res Int*, 2013: 804086.
- Nortier JL, Martinez MC, Schmeiser HH, Arlt VM, Bieler CA, Petein M, Depierreux MF, De Pauw L, Abramowicz D, Vereerstraeten P, Vanherweghem JL. 2000. Urothelial carcinoma associated with the use of a Chinese herb (*Aristolochia fangchi*). *N Engl J Med*, 342: 1686-1692.
- Ogbonnia S, Adekunle AA, Bosa MK, Enwuru VN. 2008. Evaluation of acute and subacute toxicity of *Alstonia congensis* Engler (Apocynaceae) bark and *Xylopia aethiopica* (Dunal) A. Rich (Annonaceae) fruits mixtures used in the treatment of diabetes. *Afr J Biotechnol*, 7: 701-705.
- Ogbonnia SO, Olayemi SO, Anyika EN, Enwuru VN, Poluyi OO. 2009. Evaluation of acute in mice and subchronic toxicity of hydroethanolic extract of *Parinari curatellifolia* Planch (Chrysobalanaceae) seeds in rats. *J Biotechnol*, 8: 3245-3251.
- Organisation for Economic Cooperation and Development (OECD). 2002. Guidelines for the Testing of Chemicals/Section 4: Health Effects Test No. 423, Acute oral toxicity-acute toxic class method, Paris, OECD.
- Organisation for Economic Cooperation and Development (OECD). 2000. Guidance Document on Acute Oral Toxicity. Environmental Health and Safety Monograph Series on Testing and Assessment No. 24. Paris, OECD.
- Organisation for Economic Cooperation and Development (OECD). 2008. Guidelines for the Singleton VL, Orthofer R, Lamuela-Raventós RM. 1999. Analysis of total phenols and other oxidation substrates and antioxidants by means of folin-ciocalteu reagent. *Methods Enzymol*, 299: 152-178.
- Testing of Chemicals No. 407, Repeated dose oral toxicity test method. Paris, OECD.
- The Globally Harmonized System (GHS) of Classification and Labelling of Chemicals, 2011. 4th revised edition, pp. 109-110, United Nations, New York and Geneva.
- World Health Organization (WHO). 2008. Traditional Medicine Fact sheet No. 134. Retrieved from: www.who.int/mediacentre/factsheets/fs134/en/
- Yen GC, Duh PD, Huang DW, Hsu CL, Fu TY. 2008. Protective effect of pine (*Pinus morrisonicola* Hay.) needle on LDL oxidation and its anti-inflammatory action by modulation of iNOS and COX-2 expression in LPS-stimulated RAW 264.7 macrophages. *Food Chem Toxicol*, 46: 175-185.
- Yoo KM, Lee CH, Lee H, Moon B, Lee CY. 2008. Relative antioxidant and cytoprotective activities of common herbs. *Food Chem*, 106: 929-936.
- Zolfaghari B, Iravani S. 2012. Essential oil constituents of the bark of *Pinus pinaster* from Iran. *J Essent Oil Bear*, 15: 348-351.