

Original Research Paper

## Hepatoprotective activity of aerial parts of *Otostegia persica* against carbon tetrachloride-induced liver damage in rats

Mehdi Akbartabar Toori<sup>1</sup>, Behzad Joodi<sup>2</sup>, Heibatollah Sadeghi<sup>3\*</sup>, Hossein Sadeghi<sup>4</sup>,  
Mehrzaad Jafari<sup>5</sup>, Mohammad Sharif Talebianpoor<sup>4</sup>, Foad Mehraban<sup>2</sup>, Mostafa  
Mostafazadeh<sup>2</sup>, Mehdi Ghavamizadeh<sup>2</sup>

<sup>1</sup> Social Determinants of Health Research Center, Yasuj University of Medical Sciences, Yasuj, Iran

<sup>2</sup> Student Research Committee, Yasuj University of Medical Sciences, Yasuj, Iran

<sup>3</sup> Cellular and Molecular Research Center, Faculty of Medicine, Yasuj University of Medical Sciences, Yasuj, Iran

<sup>4</sup> Department of Pharmacology, Faculty of Medicine, Yasuj University of Medical Sciences, Yasuj, Iran

<sup>5</sup> Cellular and Molecular Research Center, Faculty of Medicine, Yasuj University of Medical Sciences, Yasuj, Iran

### Article history:

Received: Dec 13, 2013

Received in revised form: Sep 11, 2014

Accepted: Feb 28, 2015

Vol. 5, No. 3, May-Jun 2015, 238-246.

### \* Corresponding Author:

Tel: +98-7433230290

Fax: +98-7433235153

sadeghi.ha@yums.ac.ir

### Keywords:

Hepatoprotective effect

*Otostegia persica*

Liver injury

Carbon Tetrachloride

Antioxidant property

### Abstract

**Objective:** To evaluate the hepatoprotective properties of *Otostegia persica* (*O. persica*) ethanol extract on carbon tetrachloride-induced liver damage in rats.

**Materials and Methods:** Fifty adult male Wistar rats were randomly divided into five groups. Group I served as normal control and was given only olive oil intraperitoneally (i.p.). Group II, III, IV, and V were administered CCl<sub>4</sub> mixed with olive oil 1:1 (1 ml/kg) i.p., twice a week for 8 weeks. Group II was maintained as CCl<sub>4</sub>-intoxicated control (hepatotoxic group). Group III, IV, and V received *O. persica* extract at a dose of 40, 80, and 120 mg/kg for 8 weeks every 48 h orally, respectively. Biochemical parameters including aspartate transaminase (AST), alanine transaminase (ALT), alkaline phosphatase (ALP), total bilirubin (TB), albumin (ALB), total protein (TP), and lipid peroxidation marker (Malonaldehyde, (MDA) were determined in serum. After 8 weeks, animals were sacrificed, livers dissected out, and evaluated for histomorphological changes.

**Results:** The administration of CCl<sub>4</sub> increased AST, ALT, ALP, TB, and MDA in serum but it decreased TP, and ALB compared with normal control. Treatment with *O. persica* extract at three doses resulted in decreased enzyme markers, bilirubin levels, and lipid peroxidation marker (MDA) and increased TP and ALB compared with CCl<sub>4</sub> group. The results of pathological study also support the hepatoprotective effects which were observed at doses of 80 and 120 mg/kg.

**Conclusion:** The results of the present study indicate that ethanol extract of *O. persica* may have hepatoprotective effect which is probably due to its antioxidant property.

Please cite this paper as:

Akbartabar Toori M, Joodi B, Sadeghi H, Sadeghi H, Jafari M, Talebianpoor MS, Mehraban F, Mostafazadeh M, Ghavamizadeh M. Hepatoprotective activity of aerial parts of *Otostegia persica* against carbon tetrachloride-induced liver damage in rats. Avicenna J Phytomed, 2015; 5 (3): 238-246.

### Introduction

Liver diseases are serious health problems. The effectiveness of treatments such as interferon, colchicine, penicillamine, and corticosteroids are inconsistent at best and the incidence of side-effects profound. In the absence of reliable liver protective drugs in allopathic medical practices, herbs play an important role in the management of various liver disorders. A number of plants have shown hepatoprotective property (Luper, 1998).

In spite of the tremendous advances in modern medicine, current therapies for hepatic diseases are not very effective yet. Because of the limited therapeutic effects and serious complications of the current medicines for the hepatic diseases, there are a growing focus on exploring novel and alternative approaches for the treatment of liver diseases. Hence a number of medicinal plants and their formulations are used to cure hepatic disorders in traditional medicine (Wagner et al., 1974; Zhang et al., 2014). To study the hepatoprotective effects of medicines and plant extracts, CCl<sub>4</sub>-induced hepatotoxicity model is used frequently. The model induces severe liver damage same as viral hepatitis (Rubinstein, 1962; Sadeghi et al., 2008).

The family of Lamiaceae, known as the mint family is one of the most diverse and widespread plant families with about 220 genera and more than 4000 species. This family is important for its flavor, fragrance or medicinal properties (Hedge, 1986; Naghibi et al., 2005 ). Some species of the family have been studied for their biological properties. Some studies have determined a variety of valuable activities such as antioxidant and free radical scavenging capacity.

The genus of *Otostegia* which is a member of this family consists of about 33 species that grows mainly in the Mediterranean regions. Several species of this family are used in traditional and modern medicine. *Otostegia aucheri*, *Otostegia michauxi*, and *Otostegia persica* (*O. persica*) are the three species of the

*Otostegia* genus which are endemic in Iran. The *O. persica* or Goldar, locally called "Gol-e-kharu", grows in south of Iran such as Fars, Sistan and Baluchestan, and Kerman provinces (Ayatollahi, 2009; Sadeghi et al., 2014; Shrififar et al., 2003). People of these regions usually use the flower and the aerial parts of the *O. persica* as a food additive and as a traditional medicine to treat inflammatory and rheumatic diseases.

It is also used as an antihistamin, antispasmodic, antiarthritis, antidiabetic, and antihyperlipidemic agent (Ghahraman, 1996; Yassa et al., 2005).

Furthermore, it has been shown that hydroalcoholic extract of *O. persica* improves morphine withdrawal syndrome (Hajhashemi et al., 2004). Studies have also demonstrated that organic extracts of *O. persica* have antimicrobial effects against Gram-positive bacteria (Asghari et al., 2006; Tofighi et al., 2009). Phytochemical studies have shown that there are many chemical components such as flavonoids, steroids, tannins, triterpenoids, and important mineral elements in aerial parts of *O. persica*. Many of these chemical constituents such as flavonoids and related compounds exhibited strong antioxidant activity (Ayatollahi et al., 2007; Tofighi et al., 2009).

The extract of aerial part and root of *O. persica* has shown significant hypoglycemic effect in diabetic rats by improving the number of  $\beta$ -cells of pancreatic islets and increasing insulin secretion (Ebrahimpour et al., 2009; Hedayati et al., 2010; Hedayati et al., 2011). In addition, it has been shown that the methanolic shoot extract of *O. persica* has hepatoprotective activity and also can decrease the hepatic dysfunction originated from diabetic disorders (Hedayati et al., 2012).

According to these properties and folk medicine usage, the aim of the current study was to evaluate the hepatoprotective

activity of hydro-alcoholic extract of *O. persica* against CCl<sub>4</sub>-induced hepatotoxicity in experimental rats.

## Materials and Methods

### Chemicals

CCl<sub>4</sub> was obtained from Merck and assay kits for the estimation of biochemical factor were purchased from Pars Azema Company, Iran.

### Animals

Male Wistar rats weighing 150-250 g were obtained from the animal breeding laboratories of Pasteur Institute (Tehran, Iran). The animals were kept under standard conditions. Housing room was maintained under constant temperature conditions (22±2 °C), relative humidity (50–60%), and lighting (12-hlight/dark cycle). Food and water were accessible ad libitum (sadeghi *et al.*, 2008). All of the experiments were performed in accordance with the Regulations of Experimental Animal Administration issued by the Ethical Committee of Yasuj University of Medical Sciences (Iran).

### Preparation of extracts

The aerial parts of the *O. persica* were collected from Firozabad, Fars, Iran. A voucher specimen was deposited in the herbarium of Kohkyloyeh and Boyerahmad Agricultural Research Center. The *O. persica* was powdered in an electrical grinder. The extraction was carried out through the maceration of dry plant powder in ethanol 70% for 48 h at incubation temperature. Then, it was extracted and ethanol was evaporated by rotary evaporator at 40-50 °C.

The extract was prepared in distilled water before use (Sadeghi and Yazdanparast, 2003; sadeghi *et al.* 2008). Acute oral toxicity study was performed as per OECD guidelines for the testing of chemicals, Test No. 423. Appropriate doses were selected for the present study (OECD, 2001).

### Experimental design

Fifty adult male Wistar rats were randomly divided into five groups. Group I served as normal control and was given only olive oil *i.p.*, Group II, III, IV, and V were administered CCl<sub>4</sub> mixed with olive oil 1:1 (1 ml/kg) *i.p.*, twice a week for 8 weeks. Group II was maintained as CCl<sub>4</sub>-intoxicated control. Groups III, IV, and V were given *O. persica* extract at doses of 40, 80, and 120 mg/kg body weight, respectively. Eight weeks after CCl<sub>4</sub> administration, and 48 h after last treatment with CCl<sub>4</sub> and *O. persica* extract, blood was collected by cardiac puncture from all of the animals for biochemical analysis (sadeghi *et al.*, 2008; Ulican *et al.*, 2003;).

### Biochemical analysis

Serum was prepared from the collected blood and subjected to biochemical measurement of different parameters, *i.e.*, AST, ALT, ALP, TB, DB,TP, and ALB (Ulican *et al.*, 2003; Aniya *et al.*, 2005) by standard automated techniques using BT 1000 Autoanalyzer and the adequate kits from pars azema, Iran .

In addition, Malonaldehyde (MDA) as a lipid peroxidation parameter was measured in serum based on the reaction of thiobarbituric acid with MDA. MDA concentration was determined by comparison to a standard curve of 1,1,3,3-TEP (tetraethoxypropane). Standard curve was made using serial dilution of TEP to yield the following test concentrations: 0, 1, 2, 2.5, 5, and 10 μM. 0.5 mL of serum or standard solutions was taken in a test tube and 2 mL of the TBA (Thiobarbituric acid)–TCA (trichloroacetic acid) (TBA-TCA reagent: 0.375% w/v TBA, 15% w/v TCA, and 0.25 N HCl) solution were added. The mixture was heated in a water bath (90-100 °C) for 15 min, cooled in a cold water bath for 10 min, and then centrifuged at 2000 g for 15 min. The absorbance of solution was read spectrophotometrically at 535 nm (Hoyland and Taylor, 1991).

## Hepatoprotective activity of *Otostegia persica* in rats

### Histopathological examination

For the histopathological study, the livers of rats were immediately removed and the tissues were fixed in 10% formalin for a period of at least 24 h. The paraffin sections were then prepared (Automatic Tissue Processor, Shandon, Citadel 1000) and cut into 5- $\mu$ m thick sections in a rotary microtome. Thereafter, the sections were stained with H&E (haematoxylin and eosin) dye (sadeghi et al. 2008). The histopathological slides were examined and photographs were taken with a photomicroscope (Olympus Ix71).

### Statistical analysis

The results are expressed as mean $\pm$ SD. The difference between experimental groups was compared using one way ANOVA (Analysis of variance) followed by Tukey's Post Hoc test using SPSS software version 17.

### Results

#### Effects of extracts on serum biochemical parameters

The effects of the *O. persica* extract on biochemical parameters of rats intoxicated by CCl<sub>4</sub> were evaluated in this study. CCl<sub>4</sub> was found to cause increases in plasma AST (136.8%), ALT (192.18%), ALP (89.96%), TB (350%), and MDA (51.14%) levels compared with those in the normal control group (Tables 1 and 2). The serum MDA (48.6%), AST (54.33%), ALT (55.98%), ALP (44.84%), and TB (71.93%) levels were significantly reduced in rats that received the extract of the *O. persica* compared with CCl<sub>4</sub> group in a dose-dependent manner. However, TP (62.5%) and ALB (79.8%) levels were significantly increased in rats that received the *O. persica* extract with CCl<sub>4</sub> group (Table 2).

Table 1. Effect of hydro alcoholic extract of aerial parts of *O. persica* on various serum biochemical parameters in rats with CCl<sub>4</sub> induced hepatotoxicity.

Group	AST(IU/L)	ALT(IU/L)	ALP(IU/L)	TB (mg/dL)
Group I (control)	183.1 $\pm$ 18.7	79.3 $\pm$ 8.4	440 $\pm$ 24.5	0.45 $\pm$ 0.01
Group II (CCl <sub>4</sub> ) = hepatotoxic	433.6 $\pm$ 23.2	231.7 $\pm$ 27.2	834.3 $\pm$ 13.7	2.03 $\pm$ 0.05
Group III (CCl <sub>4</sub> +40 mg/kg <i>O. persica</i> )	409.5 $\pm$ 38.4	223.4 $\pm$ 35.6	528.2 $\pm$ 29 $\dagger$	1.17 $\pm$ 0.07 $\dagger$
Group IV (CCl <sub>4</sub> +80 mg/kg <i>O. persica</i> )	205.9 $\pm$ 33.8 $\dagger$	124.1 $\pm$ 25.4 $\dagger$	490.3 $\pm$ 26 $\dagger$	0.61 $\pm$ 0.03 $\dagger$
Group V (CCl <sub>4</sub> +120 mg/kg <i>O. persica</i> )	198.5 $\pm$ 26 $\dagger$	102 $\pm$ 19.9 $\dagger$	460.2 $\pm$ 15.1 $\dagger$	0.57 $\pm$ 0.04 $\dagger$

Values are expressed as mean $\pm$ S.D. for 10 rats in each group.  $\dagger$ Significant reduction compared to hepatotoxic group (p<0.05).

Table 2. Effect of hydro alcoholic extract of aerial parts of *O. persica* on serum TP, ALB and MDA levels against CCl<sub>4</sub> intoxication in rats.

Group	TP(g/dL)	ALB(g/dL)	MDA(nmol/ml)
Group I (control)	7.74 $\pm$ 0.18	3.55 $\pm$ 0.11	3.05 $\pm$ 0.08
Group II (CCl <sub>4</sub> ) = Hepatotoxic	5.12 $\pm$ 0.27	2.13 $\pm$ 0.09	4.61 $\pm$ 0.27
Group III (CCl <sub>4</sub> +40 mg/kg <i>O. persica</i> )	6.97 $\pm$ 0.21*	3.31 $\pm$ 0.15*	3.19 $\pm$ 0.22 $\dagger$
Group IV (CCl <sub>4</sub> +80 mg/kg <i>O. persica</i> )	8.18 $\pm$ 0.27*	3.65 $\pm$ 0.09*	2.84 $\pm$ 0.15 $\dagger$
Group V (CCl <sub>4</sub> +120 mg/kg <i>O. persica</i> )	8.32 $\pm$ 0.15*	3.83 $\pm$ 0.12*	2.37 $\pm$ 0.14 $\dagger$

Values are expressed as mean $\pm$ S.D. for 10 rats in each group. \*Significant increase compared to hepatotoxic group (p<0.05).  $\dagger$ Significant reduction compared to hepatotoxic group (p<0.05).

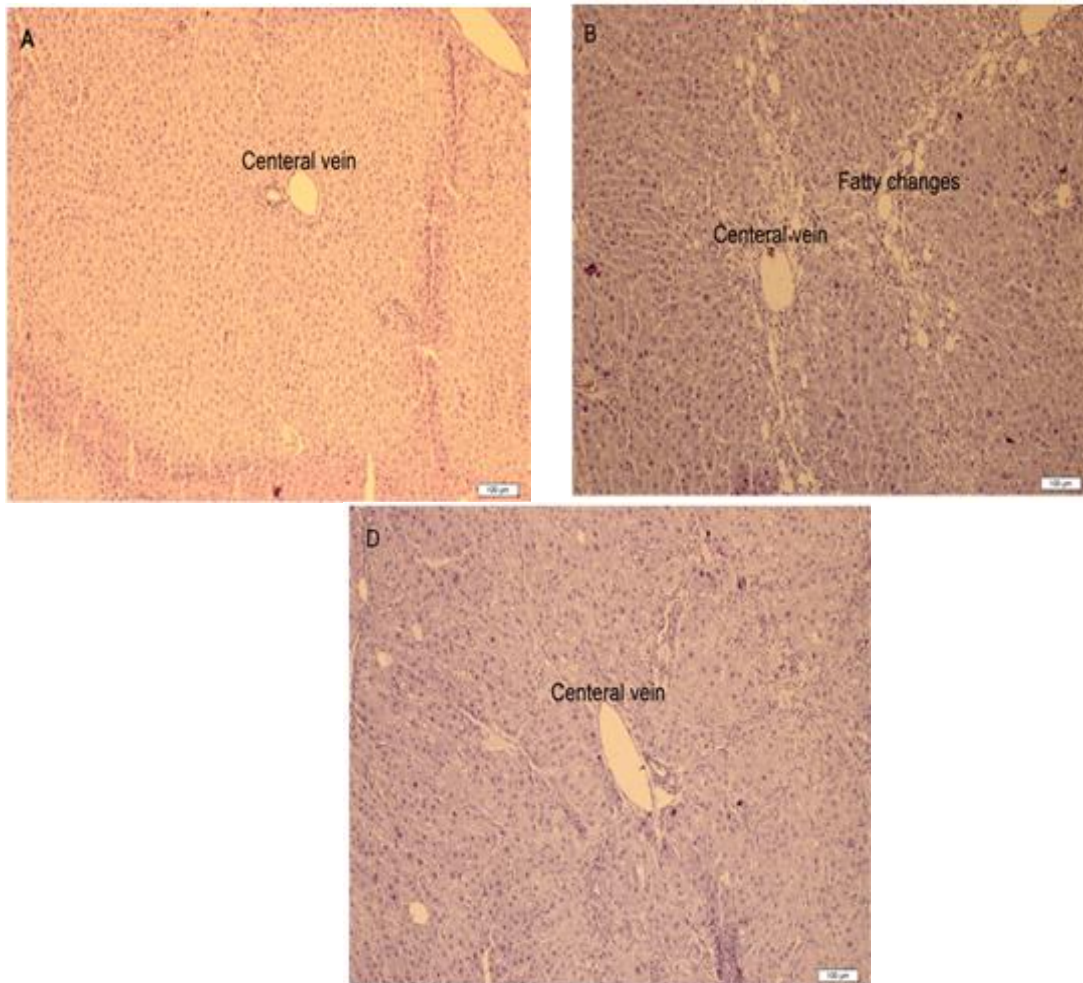


Figure 1. Liver histopathology of rats treated with  $\text{CCl}_4$  and *O. persica* extract. The liver section of each rat from different groups was stained by haematoxylin and eosin (H&E) staining, and the images were examined under light microscope. The photographs show the pathological changes in hepatic tissues (original magnification of 100): (A) Normal group, (B)  $\text{CCl}_4$ + olive oil group, and (D) 80 mg/kg B.W. of *O. persica* extract +  $\text{CCl}_4$  group.

### Histopathological examination of the liver

As shown in Figure 1, the hepatic tissues in rats of the control group exhibited normal cellular structure with distinct hepatic cells and sinusoidal spaces structure. In contrast, the liver of  $\text{CCl}_4$ -treated group exhibited the most severe damage of all groups, where the liver sections in this group showed congestion with sinusoids dilatation and ballooning degeneration (especially at the periphery of lobules). However, the pathological hepatic lesions induced by the administration of  $\text{CCl}_4$  were remarkably ameliorated by *O. persica* extract in a

dose-dependent manner and this was in good agreement with the results of serum biochemical parameters and hepatic oxidative stress level. The maximum protection was observed at the dose of 80 mg/kg B.W. of *O. persica* extract and the liver sections of the rats from these groups showed minor patho-morphological changes that were more similar to the control group.

### Discussion

$\text{CCl}_4$  is one of the most powerful hepatotoxins which is able to induce liver damage through the formation of reactive



free radicals such as trichloromethyl ( $\text{CCl}_3$ ) or trichloroperoxy radicals ( $\text{CCl}_3\text{O}^\bullet$ ). It can cause severe damages to the liver such as fatty changes, centrilobular steatosis, inflammation, apoptosis, and cell necrosis (Lutz et al., 2003; Sadeghi et al., 2008). Therefore, the main intercellular structures which are affected by  $\text{CCl}_4$  are plasma membrane, endoplasmic reticulum, mitochondria, and Golgi apparatus. (Reynolds, 1963). As a result of damaging the cell membrane of hepatocytes, enzymes release in circulation (Cullen, 2005). In the  $\text{CCl}_4$ -treated group, the levels of ALT, AST, ALP, TB, and MDA increased and the levels of TP and ALB reduced compared to the normal control group, indicating severe hepatocellular damage (Tables 1 and 2).

The signs of hepatoprotective effects of a biological agent are to maintain the normal physiological function of hepatocytes and reduce the damage of intercellular structures from exposure to the toxic agent (Balderas et al., 2007; Hui et al., 2008; Omolola and Ebenezer, 2010).

Administration of *O. persica* ethanol extract at concentrations of 80 and 120 mg/kg, for eight weeks resulted in significant ( $p < 0.05$ ) reduction of  $\text{CCl}_4$ -induced elevation of serum enzyme markers (Tables 1 and 2), comparable to the effect of several plants that have been examined for use in a wide variety of liver disorders such as *Silybum marianum*, *Picrorhiza kurroa*, *Curcuma longa*, *Camellia sinensis*, *Chelidonium majus*, and *Allium sativa* (Balderas et al., 2007; Hui et al., 2008; Omolola and Ebenezer, 2010; Luper, 1998).

Through the action of cytochrome  $\text{P}_{450}$  oxygenase system,  $\text{CCl}_4$  metabolism begins with formation of trichloromethyl free radical  $\text{CCl}_3^\bullet$ . Both CYP2E1 and CYP3A are cytochrome  $\text{P}_{450}$  isoenzymes that contribute significantly in this activation (McCay, 1984). In the presence of oxygen,  $\text{CCl}_3^\bullet$  radical is converted to trichloromethyl peroxy radical  $\text{CCl}_3\text{COO}^\bullet$  which is more active than  $\text{CCl}_3^\bullet$ . Both radicals can react

with different substances such as proteins, nucleic acids, and lipids and damaged their normal functions.

They can start the process of lipid peroxidation by reducing hydrogen from polyunsaturated fatty acids. This process by compromising membrane function and covalent binding of reactive intermediate can lead to liver cell necrosis (Recknagel, 1983; Recknagel et al., 1989). Studies have shown that  $\text{CCl}_4$  can increase the levels of  $\text{Ca}^{2+}$  in cells. This increase can activate many catabolic enzymes that destroy cytoskeletal construction and cell death through apoptosis or necrosis (Houzi et al., 2000; Nicotera et al., 1992).

MDA is an end product of lipid peroxidation which is known as a marker of oxidative stress (Pramod et al., 2008; Neetu and Sangeeta, 2011). In this study  $\text{CCl}_4$  increased MDA level in group II which is in agreement with other studies and treatment with *O. persica* extract decreased the levels of MDA in groups III to V. These results show that *O. persica* extract can ameliorate the oxidative stress induced by  $\text{CCl}_4$ .

Five compounds were isolated and purified from the methanol extract of *O. persica*. Four of them, kampferol, morin, quercetin, and isovitexin, were identified as flavonoids. These flavonoids and related compounds showed significant antioxidant activities that are comparable to butylated hydroxyanisole (BHA) and vitamin E (Shrififar et al., 2003). Antioxidants are compounds that protect organism against oxidative stress by scavenging free radicals compounds and inhibit the oxidative mechanisms that lead to degenerative diseases such as atherosclerosis, liver disease, diabetes, aging, and cancer (Sheweita et al., 2001).

Morin is a kind of flavonoid found in the plants of Moraceae family which are used as dietary agents in herbal medicine (Sreedharan et al., 2009). It has various biological effects including antioxidant properties, xanthine oxidase and protein kinase C inhibitor, anticancer, and anti-

inflammatory effects (Subash and Subramanian, 2009). Moreover, morin acts as an inhibitor of acute liver damage by blocking the expressions of inflammatory cytokines and mediators including TNF- $\alpha$ , IL-1 $\beta$ , IL-6, and iNOS (Lee *et al.*, 2008). In addition, quercetin is one of the most abundant flavonoid compounds that distributed as secondary metabolites in many plants (Liu *et al.*, 2012). It has also shown to possess anti-inflammatory, anti-allergic, anti-cancer, cardioprotective, and potent antioxidant activities (Leopoldini *et al.*, 2006). The anti-inflammatory activities of quercetin may arise from its inhibitory effects on cyclooxygenase (COX) and lipoxygenase (LOX) enzymes (Joshi *et al.*, 2011). Quercetin is considered to be a strong antioxidant due to scavenging free radicals and chelating transition metal ions that inhibits lipid peroxidation and free radical production (Coşkun *et al.*, 2004).

The results of histopathological study also support the results of hepatoprotective effect of *O. persica* extract which were observed at doses of 80 and 120 mg/kg. Simultaneous treatment of *O. persica* extract with CCl<sub>4</sub> showed significantly less damage to the hepatic cells compared to rats treated with CCl<sub>4</sub> alone. The reduction in cellular damage seen in *O. persica* extract-treated group was morphologically similar to the control group (Figure 1). Hepatoprotective mechanisms of *O. persica* on CCl<sub>4</sub>-induced acute liver damage might be due to the decreased lipid peroxidation (Nasiri Bezenjani *et al.*, 2012).

In conclusion, the results of this study demonstrated that *O. persica* extract is effective for the prevention of CCl<sub>4</sub>-induced hepatic damage in rats and therefore it could be used as a hepatoprotective agent. The protective effects against liver damage may be, at least in part, due to the free radical scavenging effect, inhibition of lipid peroxidation, and increased antioxidant activity (Yassa *et al.*, 2005). Further studies with individual active compounds of *O.*

*persica* are needed to understand the exact mechanism of hepatoprotective action.

### Acknowledgments

The authors wish to thank the deputy of research and technology of Yasuj University of Medical Sciences for providing the financial support for this study

### Conflict of interest

The authors declare that there are no conflicts of interest.

### References

- Aniya Y, Koyama T, Miyagi C, Miyahira M, Inomata C, Kinoshita S, Ichiba T. 2005. Free radical scavenging and hepatoprotective actions of the medicinal herb, *Crassocephalum crepidioides* from the Okinawa Islands. *Biol Pharm Bull*, 28:19-23.
- Asghari G, Nourallahi H, Havaie SA. 2006. Antimicrobial activity of *Otostegia persica* Boiss extracts. *Res Pharm Sci*, 1: 53-58.
- Ayatollahi SA, Kobarfard F, Asgarpanah J, Ahmed Z. 2007. Chemical constituents from *Otostegia persica*. *J Chem Soc Pakistan*, 29: 61-63.
- Ayatollahi SA, Kobarfard F, Asgarpanah J, Rahmati Roodsari M, Fanai Gh, Iqbal Choudhary M. 2009. Diterpenoids of *Otostegia persica* (Burm.) Boiss. *DARU*, 17: 290-293.
- Balderas RI, Camacho CMR, Carranza RP, Lozano GHG, Castillo ND, Alvarez M. 2007. Hepatoprotective effect of *Leucophyllum frutescens* on wistar albino rats intoxicated with carbon tetrachloride. *Ann Hepatol*, 6: 251-254.
- Coşkun O, Kanter M, Armutçu F, Çetin K, Kaybolmaz B, Yazgan O. 2004. Protective effects of quercetin, Aa flavonoid antioxidant, in absolute -induced acute gastric ulcer. *Eur J Gen Med*, 1: 37-42.
- Cullen JM. 2005. Mechanistic Classification of Liver Injury. *Toxicolo Pathol*, 33:6-8.
- Ebrahimipour MR, Khaksar Z, Noorafshan A. 2009. Antidiabetic effect of *Otostegia persica* oral extract on streptozotocin-diabetic rats. *Res J Biol Sci*, 4: 1227-1229.

## Hepatoprotective activity of *Otostegia persica* in rats

- Ghahraman A. 1996. Color atlas of Iranian flora. Research Institute of Forests and Rangelands Publishing, Tehran.
- Hajhashemi V, Rabbani M, Asghari G, Saravi Z. 2004. Effects of *Otostegia persica* on morphine withdrawal syndrome in mice. *Iran J Pharm Res*, 3: 171-175.
- Hedayati M, Pouraboli I, Mirtajaddini M. 2011. The effect of methanolic extract of *Otostegia persica* on serum levels of glucose and liver function enzymes in streptozotocin-induced diabetic male rats. *J Rafsanjan Univ Med Sci*, 10: 84-93.
- Hedayati M, Pouraboli I, Pouraboli B. 2010. Effect of methanolic extract of *Otostegia persica* on serum levels of glucose and lipids in type I diabetic male rats. *Iran J Endocrinol Metab*, 12: 435-442.
- Hedayati M, Pouraboli I, Pouraboli B, Dabiri SH, Javadi A. 2012. Effect of *Otostegia persica* extract on serum level of glucose and morphology of pancreas in diabetic rats. *Koomesh*, 13: 201-208.
- Hedge IC. 1986. Labiatae of South-west Asia: diversity, distribution and endemism. *Proceedings of the Royal Society of Edinburgh. Section B. Biol Sci*, 89: 23-35.
- Houzi D, Lekehal M, Moreau A, Moulis C, Feldmann G, Robin MA, Letteron P, Fau D, Pessayre MD. 2000. Cytochrome P450-generated reactive metabolites cause mitochondrial permeability transition, caspase activation, and apoptosis in rat hepatocytes. *Hepatology*, 32: 303-311.
- Hoyland DV, Taylor AJ. 1991. A review of the methodology of the 2-thiobarbituric acid test. *Food Chem*, 40: 271-291.
- Hui ML, Hsien CT, Chau W, Jin L, Chia L, Fen PC. 2008. Hepatoprotective effects of *Solanum nigrum* Linn extract against CCl<sub>4</sub>-induced oxidative damage in rats. *Chem-Biol Interact*, 171: 283-293.
- Joshi UJ, Gadge AS, D'Mello P, Sinha R, Srivastava S, Govil G. 2011. Anti-inflammatory, antioxidant and anticancer activity of Quercetin and its analogues. *Int J Res in Pharma and Biomed Sci*, 2: 1756-1766.
- Lee HS, Jung KH, Hong SW, Park IS, Lee C, Han HK, Lee DH, Hong SS. 2008. Morin protects acute liver damage by carbon tetrachloride (CCl<sub>4</sub>) in rat. *Arch Pharm Res*, 31: 1160-1165.
- Leopoldini M, Russo N, Chiodo S, Toscano M. 2006. Iron Chelation by the Powerful Antioxidant Flavonoid Quercetin. *J Agric Food Chem*, 54: 6343-6351.
- Liu H, Zhang L, Lu S. 2012. Evaluation of Antioxidant and Immunity Activities of Quercetin in Isoproterenol-Treated Rats. *Molecules*, 17: 4281-4291
- Luper SND. 1998. A review of plants used in the treatment of liver disease: part 1. *Altern Med Rev*, 3: 410-421.
- Lutz WD, Meinrad B, Andrese S. 2003. Hepatotoxicity and mechanism of action of haloalkanes: carbon tetrachloride as a toxicological model. *Crit Rev Toxicol*, 33: 105-136.
- McCay PB, Lai EK, Poyer JL, DuBose CM, Janzen EG. 1984. Oxygen- and Carbon-centered Free Radical Formation during Carbon Tetrachloride Metabolism "Observation of lipid radicals in vivo and in vitro". *J Biol Chem*, 259: 2135-2143,
- Naghibi F, Mosaddegh M, Motamed SM, Ghorbani A. 2005. Labiatae Family in folk Medicine in Iran: from Ethnobotany to Pharmacology. *Iran J Pharm Res*, 2: 63-79
- Nasiri Bezenjani S, Pouraboli I, Malekpour Afshar R, Mohammadi Gh. 2012. Hepatoprotective Effect of *Otostegia persica* Boiss. Shoot Extract on Carbon Tetrachloride-Induced Acute Liver Damage in Rats. *Iran J Pharm Res*, 11: 1235-1241
- Neetu S, Sangeeta S. 2011. Hepatoprotective potential of aqueous extract of *Butea monosperma* against CCl<sub>4</sub> induced damage in rats. *Exp Toxicol Pathol*, 63: 671-676.
- Nicotera P, Bellomo G, Orrenius S. 1992. Calcium-mediated mechanisms in chemically induced cell death. *Annu Rev Pharmacol*, 32: 449-470.
- OECD, 2001. OECD Guidelines for Testing of Chemicals. No 423: Acute Oral Toxicity-fixed Dose Method. Organisation for Economic Co-operation and Development, Paris.
- Omolola AA, Ebenezer OF. 2010. Hepatoprotective effects of *Vernonia amygdalina* (astereaceae) in rats treated with carbon tetrachloride. *Exp Toxicol Pathol*, 62: 197-206.
- Pramod K, Deval Rao G, Lakshmayya S, Ramachandra SS. 2008. Antioxidant and hepatoprotective activity of tubers of *Momordica tuberosa* Cogn. against CCl<sub>4</sub> induced liver injury in rats. *Indian J Exp Biol*, 46: 510-513.



- Recknagel RO. 1983. Carbon tetrachloride hepatotoxicity: status quo and future prospects. *Trends Pharmacol Sci*, 4: 129-131.
- Recknagel RO, Glende EA, Dolak JA, Waller RL. 1989. Mechanisms of carbon tetrachloride toxicity. *Pharmacol Therapeut*, 43: 139-154.
- Reynolds ES. 1963. Liver parenchymal cell injury I. Initial alterations of the cell following poisoning with carbon tetrachloride. *J Cell Biol*, 19: 139-157.
- Rubinstein D. 1962. Epinephrine release and liver glycogen levels after carbon tetrachloride administration. *Am J Physiol*, 203: 1033-1037.
- Sadeghi H, Yazdanparast R. 2003. Effect of *Dendrostellera lessertii* on the intracellular alkaline phosphatase activity of four human cancer cell lines. *J Ethnopharmacol*, 86: 11-14
- Sadeghi H, Nikbakht M, Ghaitasi I, Sabzali S. 2008. Hepatoprotective effect of *Cichorium intybus* on CCl<sub>4</sub>-induced liver damage in rats. *Afr J Biochem Res*, 2: 141-144
- Sadeghi Z, Akaberi A, Valizadeh J. 2014. *Otostegia persica* (Lamiaceae): A review on its ethnopharmacology, phytochemistry, and pharmacology. *Avicenna J Phytomed*, 4: 79-88.
- Sheweita SA, El-Gabar MA, Bastawy M. 2001. Carbon tetrachloride changes the activity of cytochrome P450 system in the liver of male rats: role of antioxidants. *Toxicol*, 169: 83-92.
- Shrififar F, Yassa F, Shafiee A. 2003. Antioxidant activity of *Otostegia persica* (Labiatae) and its constituents. *Iran J Pharm Res*, 2: 235-239.
- Sreedharan V, Venkatachalam, KK, Namasivayam N. 2009. Effect of morin on tissue lipid peroxidation and antioxidant status in 1, 2-dimethylhydrazine induced experimental colon carcinogenesis. *Invest New Drugs*, 27:21-30
- Subash S, Subramanian P. 2009. Morin a flavonoid exerts antioxidant potential in chronic hyperammonemic rats: a biochemical and histopathological study. *Mol Cell Biochem*, 327: 153-161
- Tofighi Z, Alipour F, Yassa N, Hadjiakhoondi A, Hadavinia H, Goodarzi S, Golestani R. 2009. Chemical composition and antioxidant activity of *Otostegia persica* essential oil from Iran. *Int J Essen Oil Ther*, 3: 45-48
- Ulican O, Greksak M, Vancova O, Zlatos L, Galbavy S, Bozek P, Nakano M. 2003. Hepatoprotective effect of Rooibos tea (*Aspalathus linearis*) on CCl<sub>4</sub> -induced liver damage in rats. *Physiol Res*, 52: 461-466.
- Wagner H, Diesel P, Seitz M. 1974. The chemistry and analysis of silymarin from *Silybum marianum* Gaertn. *Arznei-Forschung*, 24: 466-471.
- Yassa N, Sharififar F, Shafiee A. 2005. *Otostegia persica*. as a Source of Natural Antioxidants. *Pharm Biol*, 43: 33-38.
- Zhang ZF, Liu Y, Lu LY, Luo P. 2014. Hepatoprotective activity of *Gentiana veitchiorum* Hemsl. against carbon tetrachloride-induced hepatotoxicity in mice. *Chin J Nat Med*, 12: 0488 - 0494.